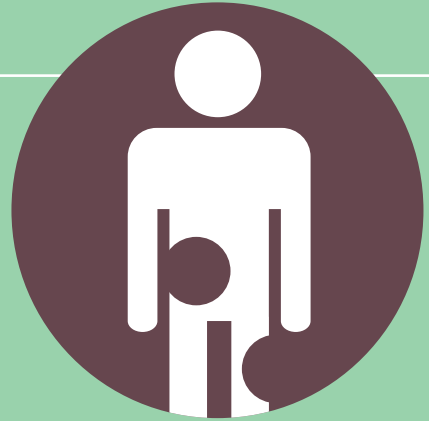

ATYPICAL WOUNDS

BEST CLINICAL
PRACTICES AND
CHALLENGES



Kirsi Isoherranen (Editor), MD, PhD, Helsinki University Central Hospital and Helsinki University, Wound Healing Centre and Dermatology Clinic, Helsinki, Finland (Kirsi.Isoherranen@hus.fi)

Julie Jordan O'Brien (Co-editor), RNP, MSc Nursing, Advanced Nurse Practitioner Plastic Surgery, Beaumont Hospital, Dublin, Ireland (jjobrien2007@gmail.com)

Judith Barker, Nurse Practitioner – Wound Management, Rehabilitation, Aged and Community Care., Adjunct Associate Professor, University of Canberra, Canberra, Australia (Judith.Barker@act.gov.au)

Joachim Dissemond (JD), Professor, MD, University Hospital of Essen, Department of Dermatology, Venerology and Allergology, Hufelandstraße 55, Essen, Germany (joachim.dissemond@uk-essen.de)

Jürg Hafner, Professor, MD, Department of Dermatology, University Hospital of Zurich, Gloriastrasse 31, Zurich, Switzerland (Juerg.Hafner@usz.ch)

Gregor B. E. Jemec (GJ), Professor, MD, Department of Dermatology, Zealand University Hospital, Roskilde, Denmark (gbj@regionsjaelland.dk)

Jivko Kamarachev (JK), MD, PHD, Department of Dermatology, University Hospital of Zurich, Gloriastrasse 31, Zurich, Switzerland (jivko.kamarachev@usz.ch)

Severin Läuchli, MD, PHD, Department of Dermatology, University Hospital of Zurich, Gloriastrasse 31, Zurich, Switzerland (Severin.Laeuchli@usz.ch)

Elena Conde Montero, MD, PHD, Hospital Universitario Infanta Leonor, Dept. of Dermatology, Madrid, Spain (elenacondemonte-ro@gmail.com)

Stephan Nobbe (SN), MD, Department of Dermatology, University Hospital of Zurich, Gloriastrasse 31, Zurich, Switzerland Department of Dermatology, Cantonal Hospital of Frauenfeld, Switzerland (stephan.nobbe@stgag.ch)

Cord Sunderkötter (CS), Professor, MD and Chair, Department of Dermatology and Venerology, University and University Hospital of Halle, Ernst-Grube-Strasse 40, Halle, Germany (cord.sunderkoetter@uk-halle.de)

Mar Llamas Velasco, MD, PhD, Department of Dermatology, Hospital Universitario De La Princesa, Madrid, Spain. (mar.llamasvelasco@gmail.com)

The document is supported by an unrestricted educational grant from PolyMem and Essity.

Corresponding author:

Editor: Kirsi Isoherranen, kirsi.isoherranen@hus.fi

Wounds Australia: www.woundsaustralia.com.au

Editorial support and coordination: EWMA Secretariat, Jan Kristensen: jnk@ewma.org

This article should be referenced as: Isoherranen K, Jordan O'Brien J, Barker J et al. EWMA document; Atypical wounds. Best clinical practice and challenges

©EWMA 2019

All rights reserved. No reproduction, transmission or copying of this publication is allowed without written permission. No part of this publication may be reproduced, stored in a retrieval system, or transmitted in any form or by any means, mechanical, electronic, photocopying, recording, or otherwise, without the prior written permission of the European Wound Management Association (EWMA) or in accordance with the relevant copyright legislation.

Although the editor, MA Healthcare Ltd. and EWMA have taken great care to ensure accuracy, neither MA Healthcare Ltd. nor EWMA will be liable for any errors of omission or inaccuracies in this publication.

Published on behalf of EWMA by MA Healthcare Ltd.

Editor: Rachel Webb

Managing Director: Anthony Kerr

Published by: MA Healthcare Ltd, St Jude's Church, Dulwich Road, London, SE24 0PB, UK

Tel: +44 (0)20 7738 5454 Email: anthony.kerr@markallengroup.com Web: www.markallengroup.com

Contents

1. Introduction	4
2. Pyoderma gangrenosum	6
3. Vasculitides as causes of wounds	11
4. Occlusive vasculopathy	21
5. Martorell HYTILU and calciphylaxis: skin infarction and acral gangrene from ischaemic arteriolosclerosis	26
6. Hidradenitis suppurativa	36
7. Malignant wounds	39
8. Artefactual ulcers	45
9. Ecthyma and ecthyma gangrenosum	47
10. Other types of atypical wounds	51
11. Histology of atypical wounds	55
12. Practical aspects of diagnosing and treating atypical wounds	61
13. Topical treatment for atypical wounds	66
14. The patient perspective	70
15. Health economy and organisation	74
16. Conclusions and future perspectives	77
17. References	79
18. Glossary	89

I. Introduction

Atypical wounds comprise approximately 20% of all chronic wounds.³⁻⁵ With an aging population and increase in comorbidities these numbers are expected to rise. Atypical wounds are considered as wounds that do not fall into a typical wound category, i.e. venous, arterial, mixed, pressure ulcer (PU) or diabetic foot ulcers (DFU).⁶⁻⁸ They are a broad spectrum of conditions or diseases caused by inflammation, infection, malignancy, chronic illnesses or genetic disorders.

An atypical wound can be suspected if the wound has an abnormal presentation or location, pain out of proportion of the size of the wound and does not heal within four to 12 weeks with a good treatment plan.⁷⁻⁹ Unfortunately, the diagnostic delay can be considerable which leads to higher mortality.¹⁰⁻¹³

Therefore, it is important that every health professional treating these wounds is familiar with this entity or at least has the knowledge to suspect an atypical wound and when to refer the patient to an expert. A multidisciplinary team (MDT) of professionals, optimally consisting of a dermatologist, vascular and plastic surgeon, rheumatologist, diabetologist, nephrologist, infectious disease specialist, psychiatrist, tissue viability nurse, podiatrist, nephrologist, psychologist, nutritionist, physiotherapist, podiatrist and a social care worker, is needed to manage this group of patients. However, it is mainly community health professionals who manages these patients on a day-to-day basis. Early diagnosis and referral to dermatologists is important as they are experts in diagnosing and treating these wounds.^{3,7,13} ***After exact diagnosis, a holistic assessment and interdisciplinary plan of care is essential for cost-effective management and to prevent recurrence.***

From the patient perspective, atypical wounds can be very painful and have prolonged healing times which lead to impaired quality of life (QoL).¹⁴ Many patients suffer daily both physically with odour, exudate, pain, reduced mobility and psychologically with negative emotions, loneliness and depression.¹⁵ Mortality rates are higher not only due to their comorbidities but also lower socio-economic circumstances leading to higher rates of suicide.¹⁶

Still, there is a dearth of literature reporting QoL or health economy in this patient population. In response to this lack of uniform data, the European Wound Management Association (EWMA) has established a working group to gather the best available knowledge on atypical wounds. This document is targeted at increasing awareness of the clinical picture, diagnosis and treatment of these wounds among health professionals and to provide practical advice on some of the challenges that typically arise, e.g. delay in diagnosis for the inflammatory and vasculopathy wounds (such as pyoderma gangrenosum (PG), an inflammatory neutrophilic disorder and cutaneous vasculitis). We hope that a systematic approach will improve care and QoL for this patient group. Lastly, it is also hoped that this document will act as a catalyst in the management of atypical wounds and fill the void that currently exists in the clinical decision making.

This document focuses on atypical wounds caused by inflammation, malignancy and chronic illnesses. Genetic disorders for example epidermolysis bullosa (EB) will not be covered. We also want to highlight that this is an educational and state of the art document. The level of evidence is not given but it is a literature review of available evidence.

The aim of the document is to:

- Present the diagnostic criteria, comorbidities and diagnostic tools for wounds defined as atypical, including practical hints for health professionals.
- Present the best available documented current treatment options. High-quality evidence is sparse, but there are retrospective and observational studies as well as some randomised prospective studies.
- Present some newer treatment options for atypical wounds.
- Reduce the diagnostic delay with these wounds by providing up to date evidence based literature on atypical wounds and an algorithm to aid clinicians in assessing these wounds in a systematic way (see algorithm in Chapter 12 Practical aspects of diagnosing and treating atypical wounds).

2. Pyoderma gangrenosum

PG is a neutrophilic dermatosis as a part of a complex systemic auto inflammatory process. The literature indicates an incidence of 0.3–1.0/100,000 inhabitants. Thus, the PG is one of the so-called orphan diseases.¹⁷ The gender distribution is described with about 3:1 more common in women. The disease can occur at any age. However, patients are frequently affected after the age of 50 years.¹⁸

Aetiology

The exact aetiology of PG is unknown. The presence of abnormal neutrophils and T-cells lead to immune dysregulation with increased levels of inflammatory mediators. It has been reported that healed sites of previous ulceration are refractory to local relapse. Therefore it is discussed that the T cell activity obligatory targets follicular adnexal structures leading to the destruction of pilosebaceous units.¹⁹ A genetic predisposition with mutations in the PEST (proline, glutamate, serine and threonine-rich) family of protein tyrosine phosphatases (PTP) has been described.²⁰

Table I. Autoinflammatory syndromes which are related to pyoderma gangrenosum (PG)

PAPA syndrome. Acronym for PG, pyogenic arthritis, and acne
PASH syndrome. Acronym for PG, pyogenic arthritis, and hidradenitis suppurativa
PA-PASH syndrome. Acronym for PG, pyogenic arthritis, hidradenitis suppurativa, and acne

The current understanding of pathophysiology is that PG is not only an isolated skin disease, but a cutaneous manifestation of a generalised inflammatory response. This is also clear when one considers that there are many associations with other inflammatory diseases. PG has also been repeatedly described as part of some rare syndromes often associated with hidradenitis suppurativa (Table 1).²¹

Comorbidities

In addition to the long-known diseases associated with PG such as chronic inflammatory bowel diseases (IBD) and inflammatory rheumatological diseases (IRD), associations with (haematological) neoplasia have also been reported. In addition, there is increasing evidence that PG may be associated with aspects of the metabolic syndrome.¹⁷ Therefore it is not surprising that there is an estimated 3-fold increase in the mortality rate amongst patients with PG¹² compared with the normal population.

Methods of diagnosis in patients with PG should therefore be individually adapted and consider various aspects of comorbidities, in particular the potentially paraneoplastic aspects.²² An interdisciplinary approach is therefore essential.

Clinical presentation

The first skin lesions of PG are erythematous papules, nodules, or pustules, which mostly develop into deep and very painful ulcerations within a few days (Fig 1 and 2). Many patients describe

the appearance of a PG after a minimal trauma. This is referred to as a pathergy phenomenon. In the early inflammatory phase, the livid colour of the surrounding erythema is very typical.²³ After the occurrence of ulcerations, the wound edges are then usually dark-red to livid in colour and with associated undermining. Some pustules can also often be found in the periwound area. Here it is important to distinguish these primarily sterile pustules from pustules as part of a bacterial superinfection, which is a frequent misdiagnosis.

A PG can occur on any part of the body. However, about 70% of all PG manifest on the lower legs.²⁴ Another predilection site is the skin around a stoma.²⁵ The resulting scars are described as cribriform (Fig 3).

PG can occur also postoperatively at the site of surgery, and typically it is first misdiagnosed as a surgical site infection. Post-surgical pyoderma gangrenosum (PSPG) has been reported most commonly after breast surgery; followed by cardiothoracic, abdominal and obstetric surgeries.²⁶ ***Negative wound swabs, no response to antibiotic treatment and worsening of the lesions following debridement and surgery are important clues for this potentially fatal condition.***^{10,27} As with non-surgical PG, the risk factors for PSPG include previous history of PG, inflammatory bowel disease, hematologic disorders, rheumatoid arthritis and a first degree relative with PG.²⁶

There are increasing scientific reports of visceral manifestations of PG. This extra-cutaneous

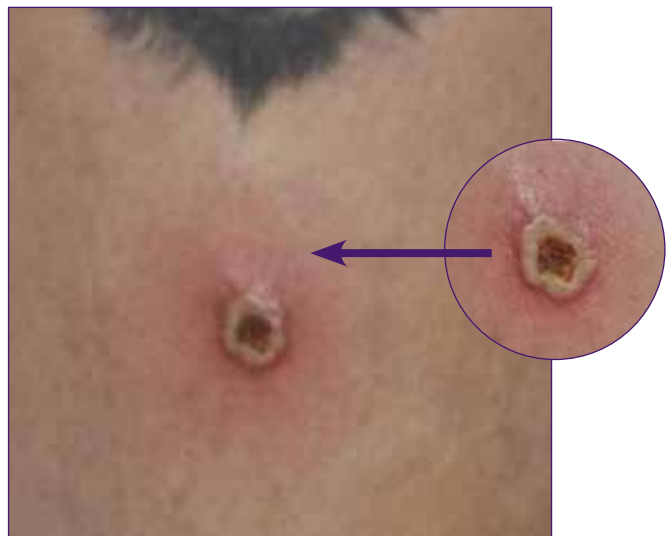

Fig 1. A young female patient with an early presentation in our clinic with a sterile pustule (picture 1, and small insert)). A biopsy was performed. Picture by Joachim Dissemond.

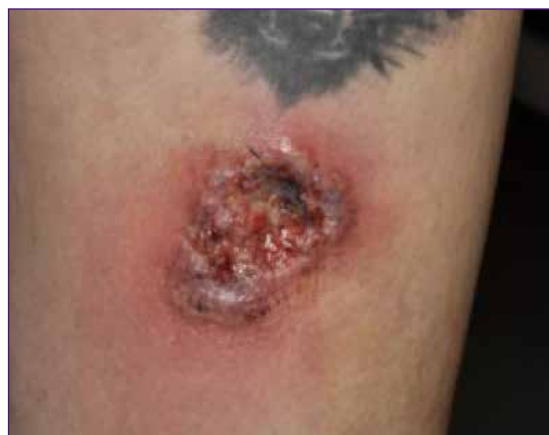

Fig 2. The patient came back two days later with a growing, painful PG. Another superficial wound, which ulcerated spontaneously, can be seen above. Picture by Joachim Dissemond.

infiltration can potentially occur in all organ systems. The most commonly reported visceral manifestation in PG is in the lungs, followed by liver, spleen, and bone. In common, these patients have aseptic abscesses.²⁸

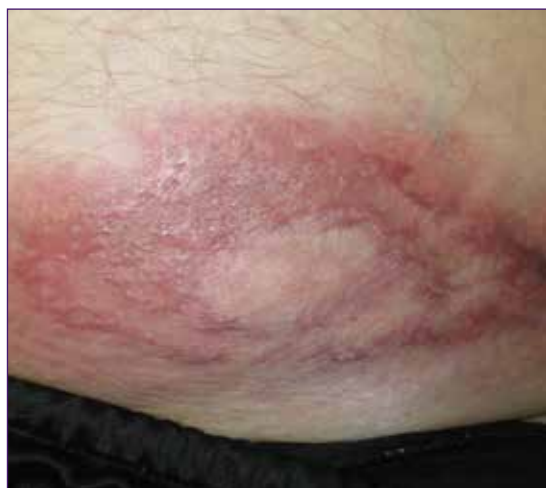

Fig 3. Cribriform scarring of a pyoderma gangrenosum (PG) ulcer. Picture by Kirsi Isoherranen.

Table 2. Diagnostic criteria of pyoderma gangrenosum (PG) according to the PARACELSUS-score

<p>Diagnostic criteria of PG according to the PARACELSUS-score Evaluation: Score ≥ 10 points = PG highly likely; < 10 points PG unlikely; VAS – visual analogue scale.</p>
<p>Major criteria (3 points) Progressive course of disease Assessment (absence) of relevant differential diagnoses Reddish-violaceous wound border</p>
<p>Minor criteria (2 points) Amelioration (alleviation) in response to immunosuppressant 'Bizarre' ulcer shape Extreme pain ($> 4/10$ VAS) Localised pathergy phenomenon</p>
<p>Additional criteria (1 point) Suppurative inflammation in histopathology Undermined wound border Systemic disease associated</p>

Diagnostics

To date a diagnosis of PG was by exclusion with some clinical similarities to other differential diagnoses like vasculitis, vasculopathy or Martorell HYTILU. The most important aspect of the differential diagnosis is the histopathological findings of a biopsy. Moreover, the PARACELSUS score for an objective method to aid the diagnosis of PG has been proposed. (Table 2)²⁹

Another diagnostic score with clinical parameters has been evaluated in 2018 (Table 3).³⁰

A pathergy test is also an option to aid diagnosis. The hyper-reactivity of the skin that occurs in response to minimal trauma is tested by inserting a sterile needle or 1ml saline into skin of the forearm. Occurrence of a red papule or pustule at the site of needle insertion 1–2 days later constitutes a positive result. However, the test is not specific for PG as it

Table 3. Criteria for the diagnosis of ulcerative pyoderma gangrenosum (PG)

Major criterion	
Biopsy of ulcer edge with neutrophilic infiltrate	
Minor criteria	
Exclusion of infection	Peripheral erythema, undermining border, and tenderness at ulceration site
Pathergy phenomenon	Multiple ulcerations, at least one on an anterior lower leg
History of inflammatory bowel disease or inflammatory arthritis	Cribriform or 'wrinkled paper' scar(s) at healed ulcer sites
History of papule, pustule, or vesicle ulcerating within four days of appearing	Decreased ulcer size within one month of initiating immunosuppressive medication(s)
For the diagnosis of PG the major criterion is obligatory and at least four of the minor criteria should be given.	

can also be positive in other neutrophilic diseases such as Behçet's disease.³¹

Therapy

The successful treatment of PG is based on various immunomodulatory and/or immunosuppressant therapies. For the selection of the appropriate individual strategy the severity as well as the acuity has to be considered.

Local therapy

For topical therapy, highly potent glucocorticoids such as preparations with clobetasol are usually applied. Especially for long-term treatments a 0.1% tacrolimus ointment is an effective alternative. The ointments should be applied as early as possible on new skin changes and also on the wound bed.³² Intra- or periwound triamcinolone can be used for an injection therapy. The sole local therapy is usually insufficient for pronounced courses of a PG, but should be used as a supportive procedure.

Systemic therapy

Glucocorticoids are currently the only approved systemic treatment and the therapy of first choice. In addition, systemic therapy with cyclosporine has good scientific evidence. Therefore cyclosporine can be used either alone or in combination with glucocorticoids. In particular, in patients with IBD or IRD, therapy with a TNF- α inhibitors are a good alternative. In this constellation they are not in an off-label use. Systemic antibiotics should only be given if signs of systemic bacterial infection are present. Moreover, it is very important to consider the use of analgesia as part the multidisciplinary therapeutic approach.

In addition, there are numerous alternative systemic therapies, most of which have been described in case series or retrospective uncontrolled cohort studies (Table 4).

Table 4. Therapeutic alternatives published in recent years for systemic treatment in patients with pyoderma gangrenosum (PG)

<ul style="list-style-type: none"> • Traditional systemic agents • Azathioprine • Dapsone • Mycophenolate Mofetil • Prednisolon • Cyclosporin • Methotrexate 	<ul style="list-style-type: none"> • Biologic agents • Adalimumab • Anakinra • Canakinumab • Etanercept • Ruxolitinib • Secukinumab • Ustekinumab
Intravenous Immunoglobulin (IVIg)	

Evidence

In a current review about systemic treatments for PG 41 studies with 704 participants were found.³³ Currently there are only two randomised controlled trials (RCT) which include the STOP-GAP study which showed in 121 patients that prednisolone and cyclosporine were similar in their effectiveness, with 15–20% complete healing after six weeks and 47% after six months.³⁴ The other RCT reported in 30 patients that infliximab was superior to placebo with a healing rate of 21% after six weeks.³⁵

Wound therapy

Local wound treatment should also be performed concomitantly in all patients. This should be based on moist wound healing principles and the patients presenting symptoms.³⁶ It is important that wound dressings can be removed atraumatically. A mechanical or surgical debridement has a potential risk of induction of a pathergy phenomenon. However, these physical treatments may be carried out during controlled inflammation by systemic immunosuppression.³⁷ Otherwise, atraumatic alternatives such as autolytic hydrogels, preparations containing proteolytic enzymes or biosurgery are possible.³⁸

Since the patients are usually given systemic immunosuppressive therapy, there is an increased

risk of infection. Therefore, antimicrobial treatments should always be included as part of the standard approach. Hyperbaric oxygen therapy (HBOT) may be considered as an additional option as it can support wound healing³⁹. If there are no clinical signs of inflammation in the course of successful therapy, negative pressure wound therapy (NPWT) and/or split-thickness skin grafting (STSG) may be considered⁴⁰.

Currently, there are no scientific studies on the importance of compression therapy in patients with PG. However, clinical experience indicates that all patients with lower extremity wounds and edema benefit from compression therapy. This compression therapy may be painful in patients with inflammatory PG. Here treatment can then be started with lower pressures of 20mmHg.⁴¹

Prognosis

Speed of healing and resolution of inflammation have been shown to be good predictors for healing of PG.⁴² The tendency to develop a new PG can potentially persist for many years.

Conclusion and recommendation

PG is a rarely diagnosed disease that results in very painful and often hard-to-heal wounds. Most patients require a combined topical and systemic immunosuppressive or immunomodulatory therapy in combination with wound therapy. After exclusion of relevant differential diagnoses a multidisciplinary diagnostic and therapeutic concept is definitely recommended.

3. Vasculitides

as causes of wounds

Vasculitis is inflammation during which the primary event is the destruction of the walls of blood vessels.

It causes wounds by ischaemic necrosis due to vessel damage and ensuing ulceration. Subsequently these wounds often present disturbed healing because of a deficit of intact or functional vessels.

A common way to categorise vasculitides is by size into large vessel vasculitis (affecting mainly aorta, large and medium size arteries), medium vessel vasculitis (affecting mainly medium and small arteries) and small vessel vasculitis (affecting mainly small arteries, arterioles, capillaries, venules). The skin harbours small blood vessels, albeit of different sizes (small arteries, arterioles, capillaries, postcapillary venules, and small veins). The arteries and veins in the panniculus and its septae are considered medium vessels in the Chapel Hill Consensus Conference (CHCC) system.⁴³

Vasculitis of small vessels often and rapidly leads to secondary thrombotic occlusion of vessels. Therefore, it is not always easy to differentiate vasculopathy from small vessel vasculitis in single biopsies.

Vasculopathy is an occlusive, initially non-inflammatory disease affecting small vessels in the skin, caused either by a systemic or local vascular coagulopathy, by embolisation, by platelet plugging or by cold-related gelling of molecules, such as cryoglobulins.

There are entities that may include both vasculitis and vasculopathy, sometimes occurring simultaneously (eg in cryoglobulinemic vasculitis, vasculitis in monoclonal gammopathy).⁴⁴⁻⁴⁶

In a recently published interdisciplinary consensus on nomenclature of cutaneous vasculitis,⁴⁷ vasculitis in the skin has been distinguished in i) a cutaneous component of a systemic vasculitis (eg cutaneous manifestations of PAN), ii) a skin-limited or skin-dominant expression or variant of a systemic vasculitis (eg cutaneous PAN or cutaneous arteritis), or iii) a single organ vasculitis (SOV) of the skin that differs with regard to clinical, laboratory, and pathological features from recognised systemic vasculitides (eg nodular vasculitis; Table 5)).

This chapter will focus on those vasculitides that cause ulcers or chronic wounds:

Medium vessel vasculitides

- Polyarteritis nodosa cutanea (cutaneous arteritis)

Small vessel vasculitides

- Immune complex vasculitides (including cryoglobulinemic vasculitis)
- Rheumatoid vasculitis and vasculitides in lupus erythematosus (LE) or other collagenous autoimmune diseases
- ANCA associated vasculitides

- Nodular vasculitis.

The aetiology differs markedly between these vasculitides as does therapy.

Medium vessel vasculitides

Polyarteriitis nodosa cutanea (cutaneous arteritis) is a chronic medium vessel arteritis which affects small arteries and arterioles in the panniculus extending to arterioles at the dermosubcutaneous junction,⁴⁸ with or without arteritis in adjacent skeletal muscle and peripheral nerves (mononeuritis multiplex). It does not directly involve venous vessels.

Aetiology

The frequent localisation on the lower legs or rarely at other sites of chronic oedema, indicate a contribution of the humoral immune response, coinciding with slowed clearing of so far unknown antigens or antibodies. Supposedly, there is a reaction to an infection such as hepatitis B, hepatitis C or streptococci or alternatively a drug. A recently described variant is associated with mutation of the CECR1-gene and deficiency of adenosine deaminase 2 (ADA2).

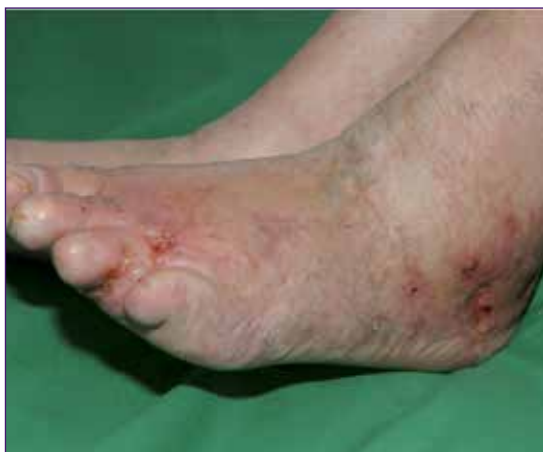

Fig 4. Cutaneous PAN. Partially ulcerated nodules, surrounded by livedo racemose Picture by Cord Sunderkötter

Clinical presentation

Cutaneous PAN (Fig 4) almost exclusively presents with locally restricted livedo and often, but not always, with palpable subcutaneous nodules. In several cases it also appears with ulcers due to ischaemic necrosis in the area supplied by the artery. Cutaneous PAN can be very painful due to ischaemia or neural involvement. Most cases of cutaneous arteritis are confined to the extremities.⁴⁹

Diagnostics

The clinical presentation and histological demonstration of arteritis confirm the diagnosis of polyarteritis nodosa.

While the vasculitis of arterioles at the dermosubcutaneous junction is usually detectable in single histological sections, the vasculitis of small arteries in the panniculus may be missing in single sections, but will be detectable in serial sections or in a repeated biopsy.

Differential diagnosis

Cutaneous PAN is more chronic and more consistent than classical systemic PAN as defined by CHCC 201243.

In contrast to microscopic polyangiitis (MPA) cutaneous PAN always starts in arterial vessels and does not involve leukocytoclastic vasculitis of postcapillary venules (while intramural or perivascular leukocytoclasia occurs).

In contrast to nodular vasculitis lesions, inflammation in cutaneous PAN does not extend past the adventia of the arterial vessel⁵⁰ and does not significantly involve the surrounding connective tissue or lobules of the panniculus. Similarly as systemic PAN, possible mimics such as vasculitides associated with ANCA, cryoglobulinemia, or RA need to be excluded as well, e.g. by laboratory parameters.

Therapy

Any potentially eliciting drug should be discontinued (eg minocycline). In case of hepatitis or strep throat anti-infective therapy is warranted. There are no controlled trials, so treatment is based on experience, case series or reviews.⁵¹ Management of pain by conventional pain medication is important. Compression therapy should also be performed and seems to be well tolerated. Local wound therapy should be performed as described above.

There is no strong evidence for drug therapy, but dapsone often is effective. If not, colchicine or methotrexate should be tried. Due to overlap with coagulopathic events low molecular weight heparin can be tried in antithrombotic dosages as used for thrombosis. In severe cases with enlarging ulcers, systemic glucocorticoids (0.4–0.5mg/kg b.w.) may be administered, followed by initiation of steroid sparing methotrexate (initially 25–30mg/week, then 10–15mg/week). Successful use of hydroxychloroquine, azathioprine, pentoxifylline, mycophenolate mofetile or high-dose immunoglobulins has been reported in individual cases.

Systemic or classical PAN

This systemic vasculitis is much rarer than originally thought. Aetiology is still an enigma, but it has been associated with hepatitis B.

Small vessel vasculitides

Small vessel vasculitides can be roughly divided into: Immune-complex vasculitides (IgA and IgG/IgM vasculitis, cryoglobulinemic vasculitis, serum sickness) and ANCA-associated vasculitides (AAV).

Immune-complex vasculitides (IgA and IgG/IgM vasculitis, cryoglobulinemic vasculitis, serum sickness) affects approximately 1–9/100 000 people worldwide.

Among the immune complex vasculitides, systemic forms and variants that are limited to the skin are both common.

Aetiology

In IgA vasculitis (IgAV) or Henoch Schoenlein Purpura deposition of poorly O-galactosylated IgA1 at glomerular capillary walls and the mesangium is one decisive feature. A number of review are available on the topic.^{52–54}

In some patients with systemic IgAV the serum levels are increased and they may form complexes with IgG and IgA antibodies. Other antigens may possibly bind to small vessels, activate or interact with endothelial cells and attract neutrophils, which become activated. This interaction results in vessel damage by respiratory burst, degranulation, and release of cytotoxic products.^{55,56}

Involvement of skin in cryoglobulinemia is due to two major mechanisms of tissue damage: i) leukocytoclastic immune complex vasculitis (type II or type III cryoglobulins; primary pathomechanisms unrelated to cold), and/or ii) occlusion of cutaneous vessels by gelling or precipitation of type I cryoglobulins (vasculopathy) in cold-exposed skin areas (all small blood vessels of the upper or deep dermis, as well as the capillaries of the fat lobule may be involved).⁵⁷ Both features may occur simultaneously and are involved at varying degrees,⁴⁵ for example deposition of immune complexes made of cryoglobulins type II and III slow blood flow and facilitate additional gelling of cryoglobulins.

Clinical presentation

The different forms of systemic immune complex vasculitides, as defined by the CHCC 2012, all present distinctive cutaneous features that are also seen in the respective skin-limited variants: round and sometimes retiform palpable purpura with predilection for the lower limbs is a constant

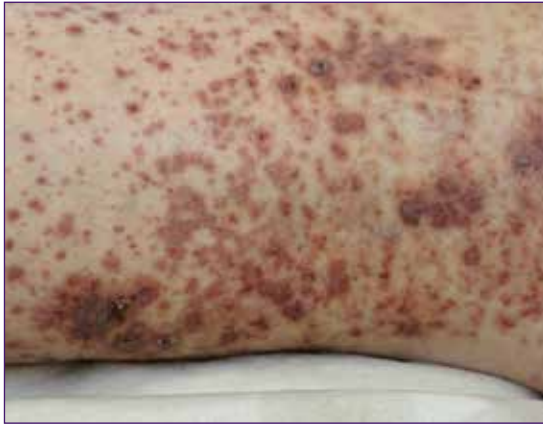


Fig 5. Immune complex vasculitis on lower leg featuring palpable and retiform purpura and incipient erosions. Picture by Cord Sunderkötter.

feature of IgA- or IgM/IgG-immune complex vasculitides (Fig 5), as is the inducibility of lesions by vasodilatory stimuli during acute phases. Ulcerations, preceded by haemorrhagic vesicles, may occur in severe forms.

Occlusive damage of vessels beyond postcapillary venules and probably also simultaneous damage to several postcapillary venules in one area can lead to bullae, erosions or (ischaemic) ulcers. Extensive involvement of vessels beyond postcapillary venules, loss of preponderance and predilection of lesions for lower legs is encountered in cases with additional pathophysiological mechanisms, such as in cryoglobulinemia, rheumatoid vasculitis, and SLE accompanied by immune complex vasculitis.

In cryoglobulinemia, leukocytoclastic vasculitis is most frequently seen in type II, less often in type III-mixed cryoglobulinemia (Fig 6).

Vasculopathy (with gelling or cryo-precipitation) with occlusion of vessels is more frequent in type I monoclonal cryoglobulinemia (often high titres of cryoglobulins) and manifests clinically as necrosis in cold-exposed, acral areas (hands, feet, lips, ears, and nose). Sometimes it is

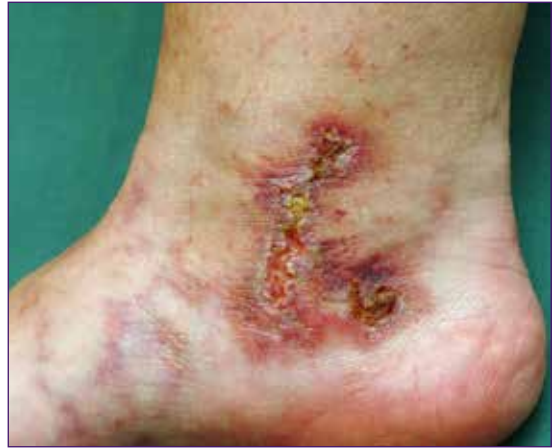

Fig 6. Livedo and retiform purpura and ulcer in cryoglobulinemic vasculitis. Picture by Cord Sunderkötter.

accompanied by livedo due to partial obstruction of blood flow.

Cutaneous IgM- or IgG immune complex vasculitis is a term not used in the original CHCC 201247. It refers to a leukocytoclastic vasculitis of mainly post-capillary venules which in the skin is indistinguishable from IgA vasculitis both histologically and clinically (palpable purpura with predilection for legs, elicitable by vasodilation). However, on (repeated) immunofluorescence tests, it is not dominant for IgA, but instead, especially in early or histamine-induced lesions,^{58,59} it shows vascular deposits of IgM and/or IgG. This category had only been described in reviews, while in studies it has been subsumed in the group of IgA-negative cutaneous immune complex vasculitides, often referred to as leukocytoclastic angiitis or hypersensitivity vasculitis.^{60,61} It probably only rarely causes ulcers.

Diagnostics

The characteristic clinical presentation and detection of IgA or IgG or IgM around vessels by immunofluorescence are usually sufficient for diagnosis. Histological demonstration of leukocytoclastic vasculitis mainly of postcapillary venules may add certainty when required. The

demonstration of leukocytoclastic immune complex vasculitis in a biopsy specimen requires a selection of a lesion between 24–48 hours old in an untreated patient. Immunofluorescence for demonstration of immunoreactants in dermal blood vessels requires a selection of a younger lesion as degrading enzymes released by leukocytes or other factors may alter the initial findings.

The ensuing diagnostic procedure is meant to assess extension of vasculitis (renal) and possible causes (see articles on vasculitis).

Differential diagnosis

Exclusion of other small vessel vasculitides.

Therapy

There are no controlled clinical trials on therapies of most immune complex vasculitides with perhaps the exception of cryoglobulinemic vasculitis,^{45,46} so the suggested procedures or treatments are based on case series, experience or reviews.⁵¹

A potentially eliciting drug should be discontinued (eg NSAID, sulphonamides, penicillin, cephaclor, diuretics, allopurinol, quinolones, hydralazine, methotrexate and contraceptives). In cases of systemic IgA-vasculitis, we recommend routine tumour screening.

Compression therapy of lower legs is a partially causative therapy as it diminishes deposition of immune complexes. Antihistamines in regular doses may be helpful and can be used for long periods.

It is often a self-limited disease, which does not require further measures and no glucocorticoids. However, especially with reference to chronic wounds, one exception is important: glucocorticoids are indicated whenever bullae or incipient necrosis occurs, as they will promptly reduce vasculitis and prevent ulcers, which are prone to heal slowly due to destroyed blood vessels.^{51,62}

Treatment in case of renal involvement is described in articles on vasculitis.

Rheumatoid vasculitis and vasculitides in LE or other collagenous autoimmune diseases

Rheumatoid vasculitis or vasculitides in LE are allocated to the category 'Vasculitis Associated with Systemic Disease' due to their involvement of different vessels, even though they are related to immune complex vasculitides.

They are prone to cause ulcers. Rheumatoid vasculitis occurs in patients with a positive test for rheumatoid factor, long standing disease and often with erosive rheumatoid arthritis. In the skin, it ranges from (often IgG/IgM-positive, but also IgA positive) LCV of post-capillary venules⁶³ to arteritis at the dermo-subcutaneous junction or in the panniculus.⁶⁴ A more frequent involvement of vessels larger than postcapillary venules distinguishes it from genuine IgA or IgG/IgM vasculitis. Therefore, it results in a more varied clinical presentation, including cutaneous ulcers, digital gangrene or nail fold infarction. Involvement of the vasa nervorum may be the cause for neuropathy. Rheumatoid vasculitis affecting muscular arteries (MVV) is distinguished from cutaneous or systemic PAN by the additional involvement of postcapillary venules as well as by the presence of rheumatoid factor and arthritis.

A similarly heterogeneous presentation of vasculitides may occur in LE (mostly cutaneous SVV, or MVV often involving peripheral nerves)⁶⁵, and more rarely in dermatomyositis or systemic sclerosis. Cutaneous vasculitis in LE may also present as immune complex vasculitis, both of which are restricted primarily to postcapillary venules.

Therapy of these vasculitides occurs as part of the treatment of the underlying systemic disease.

ANCA-associated vasculitides (AAV)

The ANCA-associated vasculitides (AAV) are a multisystem autoimmune diseases, more common in older people and in men.⁶⁶ Although rare, they will increase concomitant with the increasing average age of the population. They are a chronic disease needing long-term immunosuppressive therapy.⁶⁶

Aetiology

AAV is associated with ANCA specific for myeloperoxidase (MPO-ANCA) or proteinase 3 (PR3-ANCA). Based on pathologic and clinical features, ANCA-associated vasculitis is subdivided into microscopic polyangiitis (MPA), granulomatosis with polyangiitis (Wegener) (GPA), and eosino-philic granulomatosis with polyangiitis (Churg–Strauss) (EGPA (1)).

Presence of MPO-ANCA or PR3-ANCA is a defining feature. There is evidence both from clinical observations (rough correlation of ANCA titers with response to therapy, the use of antibody depleting therapies, animal models, and *in vitro* experiments with human neutrophils (PMN)) that both autoantibodies are pathogenic or at least one major pathophysiological factor. *In vitro*, both PR3-ANCA and MPO-ANCA IgG activate human neutrophils (PMN) to generate respiratory burst, degranulation, to release factors to activate alternative pathway of complement and neutrophil extracellular traps (NETs).⁶⁷

Clinical presentation

The cutaneous component of systemic AAV may present with different morphology, but all of them may result in ulceration and chronic wounds: a) leukocytoclastic vasculitis of postcapillary venules, sometimes extending into arterioles or small veins, clinically manifesting as haemorrhagic papules or macules, sometimes nodules and ulcers, and/or b) vasculitis of small arteries or arterioles clinically

manifesting as inflammatory retiform purpura or livedo with early lesions exhibiting prominent erythema and sometimes ulcerating nodules⁶⁸ and sometimes as digital infarcts.

The simultaneous presence of haemorrhagic papules as well as livedo or nodules is highly suspicious of an ANCA-associated vasculitis and not characteristic for immune complex vasculitis such as IgA vasculitis (HSP). It should prompt determination of ANCA in serum.

Diagnostics

Prompt diagnosis and initiation of appropriate immunosuppressive therapy is essential for optimum patient and outcomes.

It is important for clinicians taking care of wounds to suspect AAV when the heterogeneous clinical picture is associated with deteriorating condition of the patient and other symptoms such as sinusitis and bloody discharge, haemoptysis, proteinuria and haematuria or history of asthma or allergic rhinitis. Then PR3-ANCA or MPO-ANCA should be determined by ELISA and associated with an interdisciplinary procedure.

Therapy

ANCA-associated vasculitides are the only group of vasculitides mentioned here, which have been the subject of large clinical studies and therefore also of evidence-based recommendations regarding management. Since they are comparatively rare causes for atypical wounds, a detailed description of their therapy is out of scope of this chapter.

Systemic therapy should be performed by or together with a specialist. If possible, enrolment in clinical studies or registries should be chosen or offered. Rituximab has become a good alternative to the well-studied immunosuppressive chemotherapy, usually consisting of an aggressive

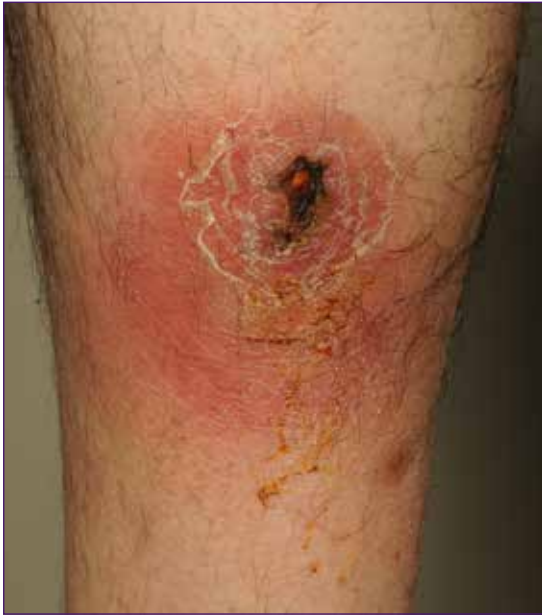

Fig 7. Nodular vasculitis (erythema induratum of Bazin).
Picture by Kirsi Isoherranen.

induction therapy aiming at remission, followed by maintenance therapy.^{66,69,70}

Nodular vasculitis (erythema induratum of Bazin)

Nodular vasculitis (erythema induratum of Bazin) is a lobular panniculitis, often associated with vasculitis of vessels in the panniculus. In presence of tuberculosis (usually with hyperergic reaction) it has been referred to as erythema induratum of Bazin⁷¹. It is a single organ vasculitis limited to the skin without systemic involvement.

Aetiology

It is probably a hyperergic (Typ IV) reaction to infectious agents such as mycobacteria tuberculosis, Hepatitis B/C, nocardia, or to rheumatoid arthritis, SLE or inflammatory bowel disease. It appears also dependent on certain constitutive traits, as it usually occurs in women with lipoedema, acrocyanosis and livedo reticularis.

Clinical presentation

Clinical features include tender erythematous subcutaneous plaques and nodules on the posterior aspects of calves, sometimes tender, mostly in middle-aged women with lipoedema (column-like lower legs), livedo reticularis or erythrocyanosis surrounding follicular pores (Fig 7). In the course of disease, most, but not all, nodules ulcerate.

Diagnostics

Diagnosis is made on clinical suspicion and ensuing histological confirmation.

There is always lobular panniculitis and often vasculitis. Affected vessels in order of frequency are: (1) small venules of fat lobules, (2) both veins of connective tissue septae and venules of fat lobules, (3) only veins of connective tissue septae, (4) veins and arteries of connective tissue septae and venules of fat lobules, (5) veins and arteries of connective tissue septae. In some cases, vasculitis could not be demonstrated within serial sections throughout the specimen.⁷¹ Nodular vasculitis with lobular panniculitis can be associated with coagulative and caseous necrosis, and (extravascular) granulomatous inflammation. According to the stage of disease, vasculitis is associated with neutrophilic, granulomatous or lymphocytic inflammation.⁵⁰

Differential diagnosis

This lobular panniculitis distinguishes it from cutaneous arteritis, and the primary localization of vasculitis and panniculitis distinguishes it from GPA and EGPA.

Therapy

In presence of tuberculosis tuberculostatic therapy (combination of three drugs for nine months). In other cases wound care, symptomatic treatment with cool dressings, compression, potassium iodatum, NSAID, systemic glucocorticoids, clofazimine, or colchicine.

Table 5. Systemic and cutaneous variants of medium-vessel and small vessel vasculitides with relevance for atypical wounds (adapted from⁴⁷)

Systemic and cutaneous variants of medium-vessel and small vessel vasculitides with relevance for atypical wounds				
CHCC2012 name	Abbreviated CHCC 2012 definition	Cutaneous component of systemic vasculitis	Skin-limited or skin-dominant vasculitis	Cutaneous presentations
Medium-vessel vasculitis = vasculitis which predominantly affects medium arteries defined as the main visceral arteries and their branches				
Polyarteritis nodosa	Necrotizing arteritis of medium or small arteries without glomerulonephritis and not associated with ANCA.	Acute arteritis of small arteries or arterioles, manifesting as digital arteritis, purpura, and/or skin nodules with ulcers.	Cutaneous arteritis (cutaneous PAN) Arteritis affecting small arteries in the panniculus extending to arterioles at the dermo-subcutaneous junction, but not to postcapillary venules.	Locally restricted livedo and often, but not always, palpable subcutaneous, often ulcerating nodules
Small vessel vasculitis = vasculitis predominantly affecting small vessels, defined as small intraparenchymal arteries, arterioles, capillaries, and (postcapillary) venules				
ANCA-associated vasculitis (Microscopic polyangiitis, Granulomatosis with polyangiitis (Wegener's), Eosinophilic granulomatosis with polyangiitis (Churg-Strauss))	Necrotizing vasculitis affecting small vessels (i.e., capillaries, venules, arterioles, and small arteries), associated with ANCA.	Vasculitis of cutaneous postcapillary venules, small veins, arterioles, and small arteries, associated with ANCA.	ANCA-associated, vasculitis limited to the skin	Palpable round and inflammatory retiform purpura, and/or b) livedo and/or c) haemorrhagic nodules and/or d) e.g. hyperplastic gingivitis (no vasculitis), especially in GPA
Immune complex vasculitides (systemic and skin-limited forms)				
IgA vasculitis (Henoch-Schoenlein)	Vasculitis, with IgA1-dominant immune deposits, affecting small vessels (predominantly capillaries, venules, or arterioles).	Leukocytoclastic IgA1-dominant vasculitis of mostly postcapillary venules and also veins or arterioles in the skin, with vascular IgA deposits	Skin-limited IgA- vasculitis Cutaneous IgA-dominant vasculitis without systemic vasculitis.	Palpable round and inflammatory retiform purpura with predilection for the legs; in severe forms haemorrhagic blisters and ulcers
Cryoglobulinemic vasculitis	Vasculitis with cryoglobulin immune deposits affecting small vessels and associated with serum cryoglobulins.	Leukocytoclastic vasculitis of small vessels and associated with serum cryoglobulins (usually type II and III)	Skin-limited cryoglobulinemic vasculitis Cryoglobulinemic vasculitis of the skin without systemic vasculitis.	Palpable round and inflammatory retiform purpura; livedo, non-inflammatory retiform purpura and haemorrhagic necrosis when cryoglobulins (e.g. type I) show gelling in cold-exposed areas

Table 5. Systemic and cutaneous variants of medium-vessel and small vessel vasculitides with relevance for atypical wounds (adopted from⁴⁷) cont

Systemic and cutaneous variants of medium-vessel and small vessel vasculitides with relevance for atypical wounds				
CHCC2012 name	Abbreviated CHCC 2012 definition	Cutaneous component of systemic vasculitis	Skin-limited or skin-dominant vasculitis	Cutaneous presentations
Systemic and cutaneous variants of vasculitis associated with probable aetiology				
Vasculitis associated with systemic disease	Vasculitis associated with a systemic disease (e.g. rheumatoid vasculitis, LE)	Cutaneous vasculitis as a component of systemic vasculitis	Cutaneous vasculitis without systemic vasculitis	Palpable round and inflammatory retiform purpura, livedo and hemorrhagic necrosis, no clear predilection for legs
Single-organ vasculitis of the skin = vasculitis in a single organ (skin) that has no features that indicate that it is a limited expression of a systemic vasculitis.				
Cutaneous IgM / IgG immune complex vasculitis	Vasculitis, with IgM and/ or IgG dominant or co-dominant immune deposits, affecting small vessels	None (not described yet)	Cutaneous IgM- or IgG-dominant/ co-dominant leukocytoclastic vasculitis of mostly postcapillary venules, without systemic involvement or cryoglobulins.	Similar as in IgA vasculitis
Nodular cutaneous vasculitis (erythema induratum of Bazin)		None	Vasculitis with lobular panniculitis of mostly small blood vessels of the fat lobule	Erythematous subcutaneous plaques and nodules on the posterior aspects of calves (sometimes ulcerated), livedo reticularis or erythrocyanosis surrounding follicular pores

Conclusions and recommendations

Vasculitides cause atypical wounds by ischaemic necrosis due to vessel damage and ensuing ulceration. Those relevant for atypical wounds are mostly small vessel vasculitides

The clinical signs provide good indications as to the respective form of vasculitis:

- Numerous lesions of palpable round or retiform purpura on lower legs (or dependent parts of the body) is almost pathognomonic for immune (complex) vasculitis such as IgA- or IgG/IgM – vasculitis
- Single painful, often ulcerated nodules surrounded by livedo (sometimes only a small zone around the ulcer) are typical for cutaneous PAN

-
- A more heterogeneous picture with a smaller number of haemorrhagic macules palpable, round or retiform purpura, ulcerating nodules and without a clear predilection for lower legs, but together with other systemic symptoms should arouse suspicion of ANCA-associated vasculitis
 - Erythematous ulcerated nodules on the posterior aspects of calves, mostly in middle-aged women with lipoedema (column-like lower legs), sometimes with livedo reticularis or erythrocyanosis surrounding follicular pores is typical for nodular vasculitis
 - Haemorrhagic necrosis in cold exposed areas in patients with cryoglobulins (mostly monoclonal type I, but also in type II or III) is typical rather for occluding vasculopathy by cryoglobulins cryogelling *in vivo* than for vasculitis due to immune-complex forming cryoglobulins
 - Treatment of wounds must include treatment of vasculitis. However, systemic treatment decisions are not always easy as good clinical studies are few. Treatment consists of searching and possibly abolishing or alleviating potential causes.

4. Occlusive vasculopathy

Occlusive vasculopathy may be defined as a blood vessels disorder mainly characterised by a diminishment or even complete occlusion of the vessel lumina.

Clinically the most characteristic finding in occlusive non-vasculitic vasculopathic disorders also known as occlusive vasculopathy is retiform purpura. **Livedo reticularis** is considered as a benign condition caused by vasospasm, with a rapidly changing pattern and will not be further discussed (Fig 8).

Livedo racemosa presents as a static network of roundish livid streaks and bands⁷² and this irregular pattern is due to permanent occlusion of a deep central vessel (Fig 9).

Other signs of occlusive non-vasculitic vasculopathies may be purpura, ulcers, infarcts and 'purple toe syndrome'.^{73,74} Occlusive vasculopathies are also associated with cerebrovascular, renal or other visceral involvement and thus, the evaluation of patients with reticulate violaceous lesions and necrotic or ulcerated lesions should trigger a workup

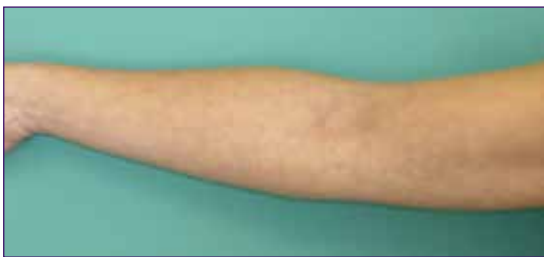

Fig 8. Livedo reticularis. Picture by Mar Llamas-Velasco.

including histopathological study and laboratory and even radiological tests.

Table 6 towards the end of this chapter shows the classification of all the different disorders that may produce occlusive vasculopathy.⁷² In the clinical setting, the first step for diagnosing both vasculitides and occlusive non-vasculitic vasculopathies is an exhaustive clinical history. Additionally, a skin biopsy is mandatory in many cases to confirm the occlusion, to rule out vasculitis and to obtain a specific diagnosis. Simultaneously, laboratory tests including complete blood count, a partial thromboplastin time, cryoglobulins, basic hepatic and renal function and ANCA, must be performed to reduce the likelihood of uncommon non-inflammatory retiform purpura and to make an accurate diagnosis.

Occlusive vasculopathies can be divided into three major groups: embolization, intravascular thrombi and coagulopathies.

A. Embolization

Cholesterol embolization

Cholesterol embolization occurs spontaneously in

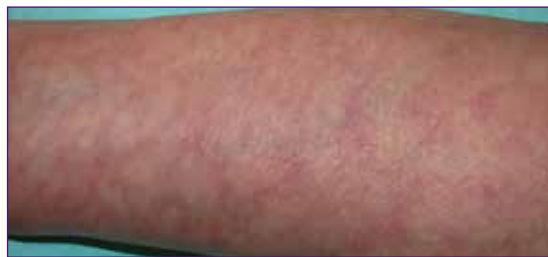

Fig 9. Livedo racemosa. Picture by Mar Llamas-Velasco.

elderly patients with severe atherosclerotic disease, as can be found in 4.4% of autopsies. Higher risk factors include catheterisation, pro-longed anticoagulation or acute thrombolytic therapy⁷⁵. Skin biopsy can be diagnostic showing elongated, needle-shaped clefts within the lumina of small arterioles, known as cholesterol clefts. A typical clinical picture is a brisk appearance of acute pain, livedo racemosa, retiform purpura, peripheral gangrene, cyanosis or ulceration on distal parts of the extremities. Birefringent crystals at the bifurcation of retinal arteries named Hollenhorst plaques, may be demonstrated by fundoscopic examination.⁷³ Treatment is mostly supportive, treating associated hypertension and underlying heart failure as well with renal replacement therapy when needed.⁷⁶

Skin metastasis

Intravascular cutaneous metastases are characterised by the presence of neoplastic cells that can involve the skin while mainly located within the lymphatic vessels, so-called 'inflammatory metastatic carcinoma', or within the blood vessels, named as 'telangiectatic metastatic carcinoma' (Fig 10).⁷⁷

Diagnosis should be confirmed by immunohistochemical studies to define the most plausible primary origin and complementary work up is mandatory to find the primary tumour if unknown or to rule out metastatic disease of another organ. Not all metastases go inside the vessels and they can be extravascular, mimicking pericytes and thus making diagnosis even more challenging.^{78,79} Treatment should be mostly directed to the primary tumour although skin metastasis can be also treated with surgical excision, cryotherapy or with electrochemotherapy.

Infective endocarditis

Endocarditis can present with septic or non-septic embolisms. Non-bacterial thrombotic endocarditis results in focal deposits of fibrin and

other blood elements on heart valves that may detach and occlude a smaller vessel (Libman-Sacks endocarditis). Typical lesions in septic endocarditis are Osler nodules, transient painful nodular lesions located on the ventral aspect of fingers and toes; and Janeway lesions, which are multiple slightly infiltrated, haemorrhagic macules, both lesions are secondary to septic emboli.^{80,81} Subungual splinter haemorrhages are quite unspecific if no additional signs or symptoms of infection are found.

Histopathology in these infections show a wide range of variation from thrombotic process without vasculitis to leukocytoclastic vasculitis, with or without thrombi, as in other forms of septic vasculitis. Septic vasculitis differs from idiopathic leukocytoclastic vasculitis by prominent intraluminal thrombi in association with minimal leukocytoclasia and, despite presenting with vascular occlusion, will not be reviewed in this chapter even when it may appear associated with infective endocarditis or with any other systemic infections.^{82,83}

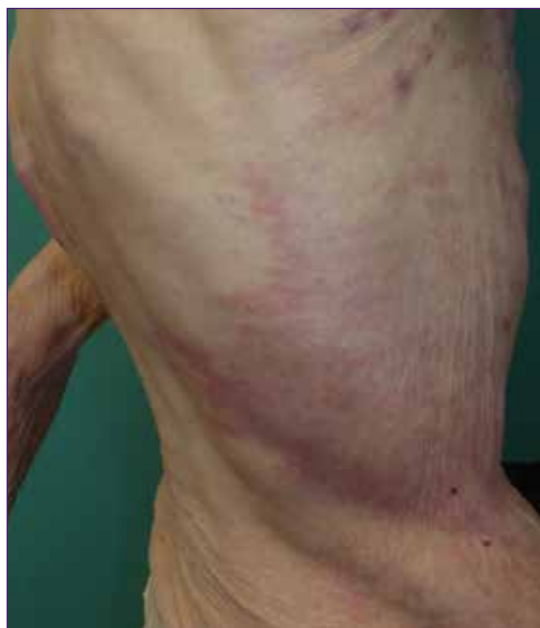

Fig 10. Stage IV breast cancer metastasis. Picture by Mar Llamas-Velasco.

Empiric antibiotic treatment in late prosthetic valves or community-acquired native valves is a combination of ampicillin/flucloxacillin or oxacillin plus gentamycin. In early prosthetic valves or nosocomial ones, vancomycin plus gentamycin and rifampicin is preferred, an empiric treatment that must be changed when microorganism susceptibility pattern is later known.⁸³

B. Intravascular Thrombi

Heparin-induced skin necrosis

Heparin-induced skin necrosis presents as purpuric plaques with or without necrosis at the site of heparin injection 5–14 days after beginning treatment. It also affects distant sites while platelet number is characteristically reduced.⁸⁴ It is caused by the appearance of an antibody, which binds complexes formed by heparin with protein factor 4 that is located in the platelets surface. Histopathology shows a non-inflammatory occlusion by an eosinophilic thrombi composed of a platelet plug known as a 'white clot', involving both arterial and venous dermal vessels in the superficial and deep plexus.⁸⁴

Other diseases such as thrombocytosis, polycythaemia vera and myelodysplastic may present similar clinicopathological picture and thus, the patient must be referred to haematology department if blood test suggests these type of diseases.

Cryoglobulinemias

Cryoglobulinemias are classified as monoclonal, mixed or polyclonal. Only type I cryoglobulinemia manifests with an occlusive vasculopathy. Acral sites are more frequently involved (Fig 11).

Histopathology is diagnostic, as the lumina of small blood vessels appear filled by a homogeneous, PAS positive, eosinophilic material. Although up to 20% of the cases are idiopathic, it can be associated

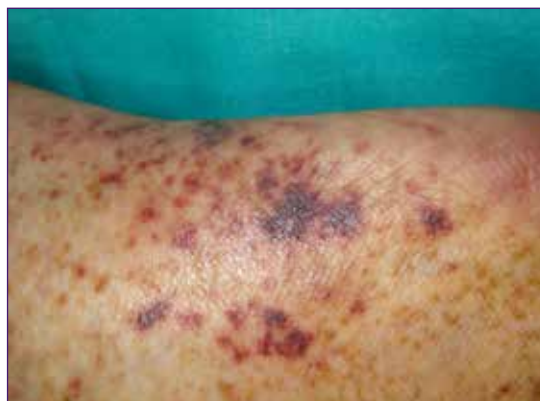


Fig 11. Cryoglobulinemia. Picture by Mar Llamas-Velasco.

to haematological diseases such as multiple myeloma, Waldenström's macro-globulinemia, leukaemia or lymphoma. The treatment of the B-cell lymphoproliferative disorder as well as the avoidance of cold temperatures improves the cryoglobulinemic vasculitis although other additional treatments may be used such as rituximab, plasma exchange, corticosteroids or iloprost and some authors have proposed the use of bortezomib.^{85,86} Crystalglobulinemia, rarely reported in the skin, is considered as a severe type of cryoglobulinemia usually appearing along with a rapidly progressive renal failure, peripheral neuropathy and polyarthropathy.^{72,87}

C. Coagulopathies

Systemic coagulopathies

Coumarin/Warfarin-induced skin necrosis affects patients with a congenital or acquired protein C and S deficiency when they need warfarin as it is a vitamin K antagonist⁷³. First skin lesions appear 3–5 days after the treatment as purpuric maculopapular or urticarial lesions mostly affecting fatty areas. Concomitant use of heparin before starting warfarin treatment and during the first five days of warfarin treatment may prevent the disease⁸⁸. Treatment with vitamin K and fresh-frozen plasma may reverse the effects.⁸⁹

Hypercoagulable states, that are classified into primary (such as factor V Leiden mutation, pro-thrombin G20210A mutation and hyperhomocysteinemia as characteristic examples) and secondary states such as immobilisation after surgery, cancer or sepsis, are included within the wide list of hypercoagulability states that may produce thrombosis and a vascular occlusion thus leading to necrosis and ulceration in the skin.⁹⁰ Primary states control often requires consultation to haematologist and secondary states to control the predisposing factors.

Purpura fulminans (PF) is a dermatologic emergency where non-inflammatory, retiform, confluent purpura evolves rapidly into necrotic lesions and underlying conditions may include severe systemic coagulopathies, drugs intake, mostly cocaine adulterated with levamisole and disseminated infections^{82,91,92}. Supportive treatment (blood transfusion, heparinisation, anti-Xa agents, synthetic protease inhibitors, natural protease inhibitor, and fibrinolytic treatment) as well as treating the underlying causes; with antibiotics combined with surgical drainage when infection is underlying or; anticancer drugs with surgery when there is a malignant disease are needed.

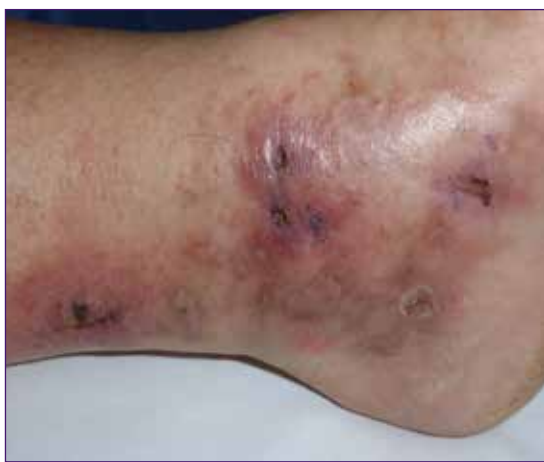

Fig 12. Livedoid vasculopathy. Picture by Mar Llamas-Velasco.

Livedoid vasculopathy (LV)

LV is also known as PURPLE (painful purpuric ulcers with reticular pattern of the lower extremities).⁹³ LV often is associated with several hypercoagulability states but the pathogenesis is not completely understood.⁹⁰ Characteristic clinical presentation is painful, punched-out ulcers that heal leaving white stellate scars (atrophie blanche) with peripheral telangiectasia appearing mostly on distal lower extremities in females (Fig 12).

As LV may coexist with cutaneous polyarteritis that may also clinically mimic LV,⁹⁴ skin biopsy is mandatory to rule out the segmental involvement of a muscular vessel.⁹⁵ Many therapies have been tried from antiaggregants, analgesics, anti-inflammatory drugs, pentoxifylline, hyperbaric oxygen therapy (HBOT) to systemic anticoagulants and even fibrinolytic therapy and vasoactive drugs.^{96,97} Rivaroxaban 10–20mg daily seems a promising drug.^{98,99}

Conclusion

Clinicopathological evaluation of reticulated violaceous lesions that may present with skin ulcers, will lead to an accurate diagnosis of occlusive vasculopathy in order to establish risk of other visceral involvement and to properly choose a first line empirical treatment.

Skin biopsy and laboratory tests including complete blood count, a coagulation study, cryoglobulins, basic hepatic and renal function as well as ANCA should be done.

Treatments can be classified as the ones focused in the control of the predisposing factors but anticoagulants, antiaggregants, vasoactive drugs and even plasma exchange or anti-inflammatory treatments or antibiotic agents may be needed depending on the aetiology of the disease.

Table 6. Classification of occlusive vasculopathies. Based on previously published table⁷²

Types	Clinicopathological entities	
Embolization	Endogenous material	Cholesterol emboli, oxalate emboli, crystal globulin vasculopathy
	Tumours	Atrial myxoma, angiosarcoma, intravascular lymphoma, crystal globulin vasculopathy, intravascular metastasis
	Abnormal benign cells	Intralymphatic histiocytosis, reactive angioendotheliomatosis
	Foreign components	Infective: Infective endocarditis Foreign material: drug-eluting beds
Thrombi	Platelet plugging	Heparin-induced skin necrosis Thrombocytosis secondary to myeloproliferative disorders Paroxysmal nocturnal haemoglobinuria Thrombotic thrombocytopenic purpura
	Cold-related agglutination	Cryoglobulinemia Cryofibrinogenemia Cold agglutinins
	Infectious microorganism invading vessels	Ecthyma gangrenosum Opportunistic fungi, for example aspergillosis Disseminated strongyloidiasis Lucio's phenomenon of leprosy
Coagulopathies	Systemic coagulopathies	Defects of C and S proteins Coumarin-induced skin necrosis Disseminated intravascular coagulation Antiphospholipid antibody/ lupus anticoagulant syndrome
	Vascular coagulopathies	Sneddon's syndrome Livedoid vasculopathy Degos disease
	Red cell occlusion syndromes	Stress reticulocyte adhesion
Miscellaneous	Calciphylaxis Hydroxyurea-induced ulcers (see picture in Ch. 10 Other types of atypical wounds) Occlusive vasculopathy induced by cocaine-levamisole	

5. Martorell HYTILU and calciphylaxis: skin infarction and acral gangrene from ischaemic arteriolosclerosis

Martorell hypertensive ischemic leg ulcer (HYTILU) and calciphylaxis, also known as calcific uremic arteriopathy (CUA) share a common clinical pattern and histological hallmarks: Skin infarction and acral gangrene caused by ischaemic arteriolosclerosis (Fig 13).

Arterioles show a hypertrophic media with or without a miniaturised form of Mönckeberg medial calcinosis and with or without intima hyperplasia, which result in a narrow vessel lumen (Fig14).¹⁰⁰

Clinically both entities share the same distribution of skin infarctions, which can be located distally (characteristic laterodorsal location including the Achilles tendon) or proximally and centrally (medial thighs, abdominal apron, breasts, lateral upper arms). Acral gangrene of fingers, toes or penis occurs exclusively in calciphylaxis.¹⁰¹⁻¹⁰⁷

'Classical' calciphylaxis occurs in patients with end-stage renal disease (ESRD)¹⁰⁴ and rarely in patients without ESRD who exhibit morbid obesity

with essential hypertension and diabetes type 2100.¹⁰⁸⁻¹¹⁰ Martorell HYTILU¹¹¹ occurs in patients with usually long-standing and well-controlled essential hypertension. Approximately 60% of Martorell HYTILU patients also have diabetes type 2.^{101,103,106,112} By definition, Martorell HYTILU patients have no ESRD; otherwise they qualify for the distal form of 'classical' calciphylaxis.¹⁰⁰

Both Martorell HYTILU and calciphylaxis can be lethal. The lethality of Martorell HYTILU may reach 10%, particularly when patients are unnecessarily exposed to high-dose immunosuppression for erroneous diagnosis of pyoderma gangrenosum.¹⁰³ The one-year-mortality rate of central forms of calciphylaxis has been reported around 40–50% in patients with ESRD and 25% in patients without ESRD.^{104,113}

In many countries the awareness of Martorell HYTILU and calciphylaxis is still low. Both entities are hardly mentioned in medical textbooks or lectures, except in France, where Martorell HYTILU enjoys high awareness under the term **angiodermite nécrotique**.^{101,106,114-117}

	Calciphylaxis in end-stage kidney disease or after successful kidney transplant	Calciphylaxis in normal renal function and normal parathyroid function
Distal pattern (below knee, in calciphylaxis fingers, toes, penis)	 <p>Calciphylaxis, distal pattern</p>	 <p>Martorell HYTILU (hypertension)</p>
Proximal pattern (thighs, abdominal apron, trunk)	 <p>Calciphylaxis, proximal pattern</p>	 <p>Eutrophication in morbid obesity</p>

Fig 13. The four clinical patterns of Martorell hypertensive ischemic leg ulcer, calciphylaxis in normal renal and parathyroid function, and calciphylaxis, peripheral and central pattern. Hafner J. Calciphylaxis and martorell hypertensive ischemic leg ulcer: same pattern - one pathophysiology. *Dermatology* 2016; 232(5):523–533, reproduced with the permission of S. Karger AG, Basel, Switzerland.

Pathophysiology

Pathophysiology of calciphylaxis in end-stage renal disease (ESRD)

Calciphylaxis occurs in approximately 35/10,000 ESRD patients on dialysis.¹⁰⁴ The typical period of onset is 35–105 months after initiation of dialysis.¹⁰⁴ Calciphylaxis is associated with the following risk factors:^{118,119} Diabetes, obesity, female sex, dependence on dialysis, calcium and phosphate disturbances, overuse of vitamin D

and calcium substitutes and/or calcium-based phosphate binders and vitamin K depletion (from malnutrition or malabsorption) or medication with vitamin K antagonists (hazard ratio 3-13!).^{120,121}

Matrix Gla protein (MGP) is a vitamin K-dependent strong protector from extraskeletal calcification^{121–123} which simultaneously inhibits the procalcifying proteins BMP 2+4.^{120,124} MGP and fetuin A deficiency are regarded essential risk factors

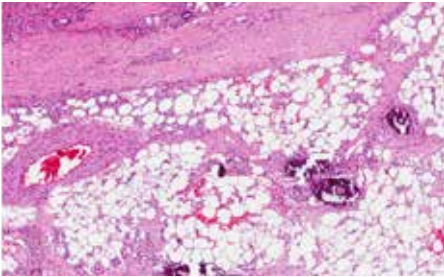
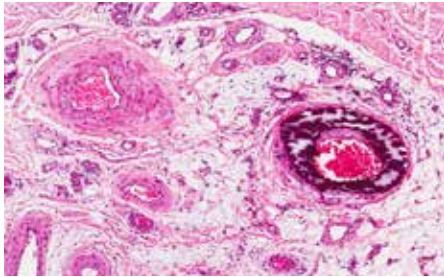
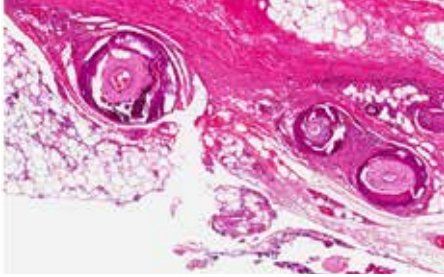
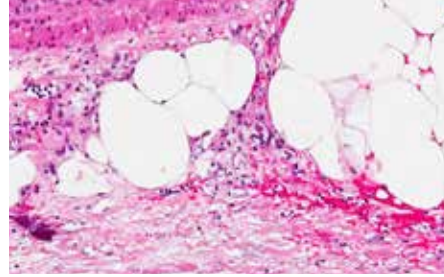
	Calciphylaxis in end-stage kidney disease or after successful kidney transplant	Calciphylaxis in normal renal function and normal parathyroid function
Distal pattern (below knee, in calciphylaxis fingers, toes, penis)	 <p>Calciphylaxis, distal pattern</p>	 <p>Martorell HYTILU (hypertension)</p>
Proximal pattern (thighs, abdominal apron, trunk)	 <p>Calciphylaxis, proximal pattern</p>	 <p>Eutrophication in morbid obesity</p>

Fig 14. The four identical histological patterns. Hafner J. Calciphylaxis and Martorell hypertensive ischemic leg ulcer: same pattern - one pathophysiology. *Dermatology* 2016; 232(5):523–533, reproduced with the permission of S. Karger AG, Basel, Switzerland

of calciphylaxis. Vitamin K antagonists (warfarin, phenprocoumon, acenocoumarol) therefore increase the risk of developing calciphylaxis.^{120,121}

Subcutaneous obliterating arteriolosclerosis (vessel diameter: 100–600µm) with medial hypertrophy,

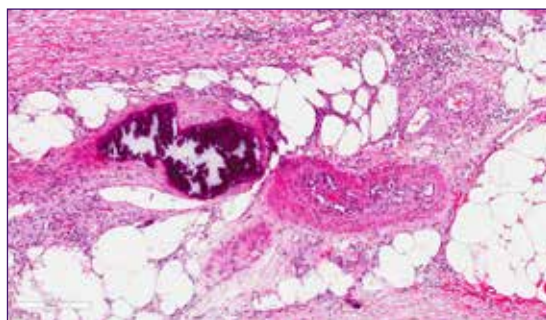


Fig 15. Subcutaneous arteriolosclerosis, with and without medial calcification, adjacent dermal necrosis. Picture by Jürg Hafner.

with or without Mönckeberg medial calcification and with or without endothelial hyperplasia (Fig 15) are the immediate cause of skin infarction and acral gangrene.^{103,112,125,126}

Pathophysiology of calciphylaxis without ESRD ('eutrophication')

Calciphylaxis without ESRD exclusively occurs in patients with morbid obesity who commonly have type 2 diabetes and essential hypertension.^{108–110}

Nephrologists regard calciphylaxis without ESRD as a subform of calciphylaxis, whereas we suggested the hypothesis that it represents the proximal variant of Martorell HYTILU.¹⁰⁰

Pathophysiology of Martorell HYTILU

Martorell HYTILU is characterised by skin infarctions in a typical laterodorsal location of the legs and over the Achilles tendon (Fig 16).^{101,103,105,106,112,114–117}

They are associated with essential hypertension (usually long-standing and well-controlled) (100%), diabetes type 2 (60%) and perhaps also with vitamin K antagonist medication. In 50% of patients Martorell HYTILU is accompanied by common peripheral arterial disease (PAD), but 50% of patients show normal peripheral arteries of the legs.¹⁰³

Common characteristics of Martorell HYTILU and calciphylaxis

Common atherosclerosis results from inflammation and remodelling of the arterial vessel wall. Hypertension, diabetes, dyslipidaemia and smoking are the four major cardiovascular risk factors.

We suggested the hypothesis that arteriolosclerosis in Martorell HYTILU and calciphylaxis without ESRD, and to some extent ‘classical’ calciphylaxis in ESRD, too, share the same risk factors (Table 7).¹⁰⁰

(A) Hypertension (HT) is always present in Martorell HYTILU (primary HT),^{101,103,105,106,112,114-117} in calciphylaxis without ESRD¹⁰⁸⁻¹¹⁰ and in most instances of ‘classical’ calciphylaxis in ESRD (renal hypertension).

(B) Diabetes can be found in 60% of patients with Martorell HYTILU, in 100% of patients with calciphylaxis without ESRD,¹⁰⁸⁻¹¹⁰ and is the most frequent cause of ESRD.

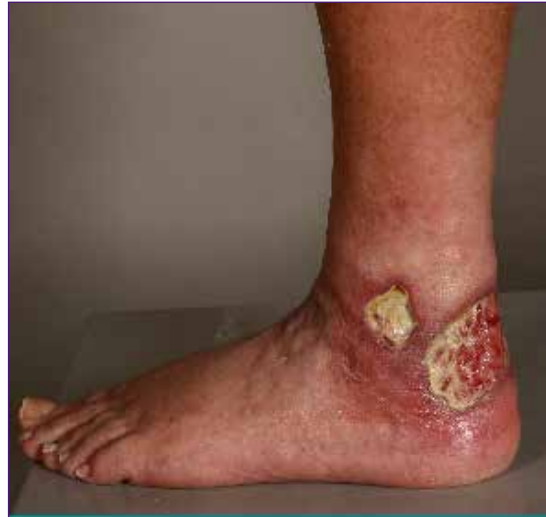

Fig 16. A 66-year-old-male, Martorell hypertensive ischemic leg ulcer. Laterodorsal skin infarction, involving the area over the Achilles tendon. Picture by Jürg Hafner.

(C) Vitamin K antagonists are an established risk factor of ‘classical’ calciphylaxis in ESRD.^{120,123} It is plausible to hypothesise that vitamin K antagonists may be a risk factor of Martorell HYTILU and calciphylaxis without ESRD, too, however, this has not yet been scientifically proven.

(D) Raised calcium and phosphate levels and disturbed bone mineralisation are regarded major risk factors of ‘classical’ calciphylaxis in ESRD.^{118,119,126-134}

Table 7. Cardiovascular risk factors of arteriolosclerosis

	Normal renal function	Chronic renal insufficiency
Distal pattern of necrosis	<p>Martorell hypertensive ischemic leg ulcer</p> <p>Arterial hypertension (primary, essential hypertension)</p> <p>Diabetes mellitus (type 2)</p> <p>Vitamin K antagonists (fetuin A inactivation)</p>	<p>Calciphylaxis, distal pattern</p> <p>Renal hypertension (secondary, renal hypertension)</p> <p>Diabetes mellitus (type 1 or type 2)</p> <p>Vitamin K antagonists (fetuin A inactivation)</p> <p>2° or 3° Hyperparathyroidism</p>
Proximal pattern of necrosis	<p>Calciphylaxis in normal renal and parathyroid function</p> <p>Morbid obesity with:</p> <ul style="list-style-type: none"> • Arterial hypertension (primary, essential hypertension) • Diabetes mellitus type 2 • Vitamin K antagonists (fetuin A inactivation) 	<p>Calciphylaxis, proximal pattern</p> <p>Renal hypertension (secondary, renal hypertension)</p> <p>Diabetes mellitus (type 1 or type 2)</p> <p>Vitamin K antagonists (fetuin A inactivation)</p> <p>2° or 3° Hyperparathyroidism</p>

Table 8. Patterns of location

	Normal renal function	Chronic renal insufficiency
Distal pattern of necrosis (skin infarction)	Martorell hypertensive ischemic leg ulcer Laterodorsal leg Achilles tendon	Calciphylaxis, distal pattern Laterodorsal leg Achilles tendon Finger, toe, penis necrosis or gangrene
Proximal pattern of necrosis (skin infarction)	Calciphylaxis in normal renal and parathyroid function Medial thigh Abdominal apron Female breasts Lateral upper arms	Calciphylaxis, proximal pattern Medial thigh Abdominal apron Female breasts Lateral upper arms

Clinical presentation and differential diagnosis

Skin infarction typically begins as dusky discoloration, violaceous spot or plaque that becomes overtly necrotic within a few days.¹⁰⁴ The necrotic area is irregular and polycyclic. A livedo pattern is often found around the necrosis, and the wound border is typically inflamed and undermined. Most patients experience excruciating pain which is difficult to control with common analgesia, including opioids.^{103,104} Acral gangrene of fingers, toes and penis can occur during ‘classical’ calciphylaxis in ESRD.^{102,104} The location of necrosis mostly follows a typical pattern: Laterodorsal legs including the Achilles tendon,¹⁰⁵ as well as the medial thighs, abdominal fat apron, female breasts, and lateral upper arms (Table 8).¹⁰³

Difficulty of distinguishing/confounding Martorell HYTILU from PG or necrotising cutaneous vasculitis

Martorell HYTILU can easily be overlooked or interpreted as PG or necrotising vasculitis by physicians who are unaware of the entity. In a series of 31 patients we described in 2010, half of the patients erroneously received high-dose immunosuppression for supposed PG.¹⁰³

The clinical aspect of the wound in Martorell HYTILU and calciphylaxis, respectively, are indeed

difficult to distinguish. Both entities develop progressive, polycyclic skin necrosis with a very painful, violaceous and undermined border:

Martorell HYTILU, which is based on arteriosclerotic skin infarction, tends to result in a ‘black’ skin necrosis involving all skin layers, sparing the fascia. Patient history includes longstanding and well-controlled primary hypertension and in 60% of patients type 2 diabetes. Malignancies, particularly hematoproliferative disorders and myeloma, and inflammatory bowel disease are not associated with Martorell HYTILU. Martorell HYTILU does not respond to systemic glucocorticosteroids or other systemic immunosuppressives, except that the tissue inflammation around the skin ulcer may clinically appear attenuated.

PG, which is based on uncontrolled neutrophil activation, initially results in a more superficial necrotic ‘liquefaction’ of the skin necrosis that responds to and heals under systemic glucocorticosteroids. Skin necrosis in PG is often not ‘black’, and commonly stops at the deeper dermis. Hematoproliferative disorders are found associated in 20% and inflammatory bowel disease in 10% patients. The majority of PG are located at the legs, and hypertension and diabetes are associated with PG, as well.^{12,17,135}

Necrotising vasculitis commonly shows bilateral multiple, symmetric round and deep skin ulcers at the legs, buttocks, lower back, and less frequently arms and shoulders. Palpable purpura is present during the initial phase of disease. Infections are the most common trigger, and organ involvement, particularly glomerulonephritis, have to be searched for and treated as indicated.^{47,136}

Ecthyma gangrenosum (EG) can be seen in immunocompetent patients with skin infections with *Streptococci* spp. or *Pseudomonas* spp., (eg after hot tub baths), as well as in immunosuppressed patients with skin infections with unusual strains, (eg atypical mycobacteria). EG can bear close resemblance with PG or vasculitis skin ulcers, and needs to be actively considered in the mentioned settings.¹³⁷

Examination, and indication of an appropriate skin biopsy

(A) All patients with a suspicion of Martorell HYTILU or calciphylaxis should have a screening examination to exclude PAD. Approximately 50% of patients with Martorell HYTILU have PAD, which usually is treated by angioplasty (PTA). Restoration of arterial inflow by PTA¹⁰³ improves chance of healing.

(B) Microbiology using a swab or other culture technique (eg PCR or biopsy) is important regarding

management of critical colonisation and/or infection and perioperative antibiotic prophylaxis during debridement and split skin transplantation.

(C) The necessity of performing skin biopsy to confirm subcutaneous arteriolosclerosis as underlying pathology is controversial. The French school suggests to base a diagnosis of Martorell HYTILU on the clinical pattern alone, provided that the clinical picture is characteristic^{106,117}.

They argue that particularly in small skin ulcers a biopsy may iatrogenically worsen the condition, and that subcutaneous arteriolosclerosis is a non-specific histopathologic finding, especially in the elderly population. It is recommended to perform a diagnostic skin biopsy in all cases of Martorell HYTILU where PG and/or necrotising vasculitis or where further pathologies have to be ruled out, or when major wound surgery is required anyway.

It is important not to perform a small punch biopsy, because histopathology of small samples can be misleading and show dense neutrophil infiltrates in the necrotic superficial dermis in all suspected differential diagnoses, leading to erroneous 'confirmation' of 'PG'. Instead, a 3–6cm long and 4–5mm wide spindle shape biopsy extending from healthy skin into the necrotic area and including all three skin layers down to fascia is collected in local anaesthesia.¹⁰³ These narrow and long biopsy wounds can be closed with absorbable suture material (Fig 17).

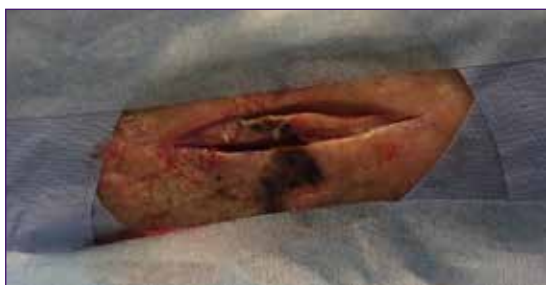

Fig 17. Spindle shape biopsy including subcutaneous fat, 6 cm long and 6 mm wide. Picture by Jürg Hafner.

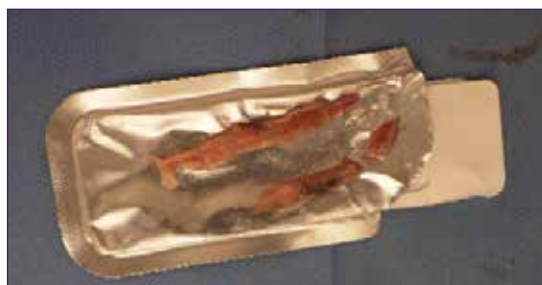

Fig 18. Spindle shape biopsy including subcutaneous fat, 6 cm long and 6 mm wide. Picture by Jürg Hafner.

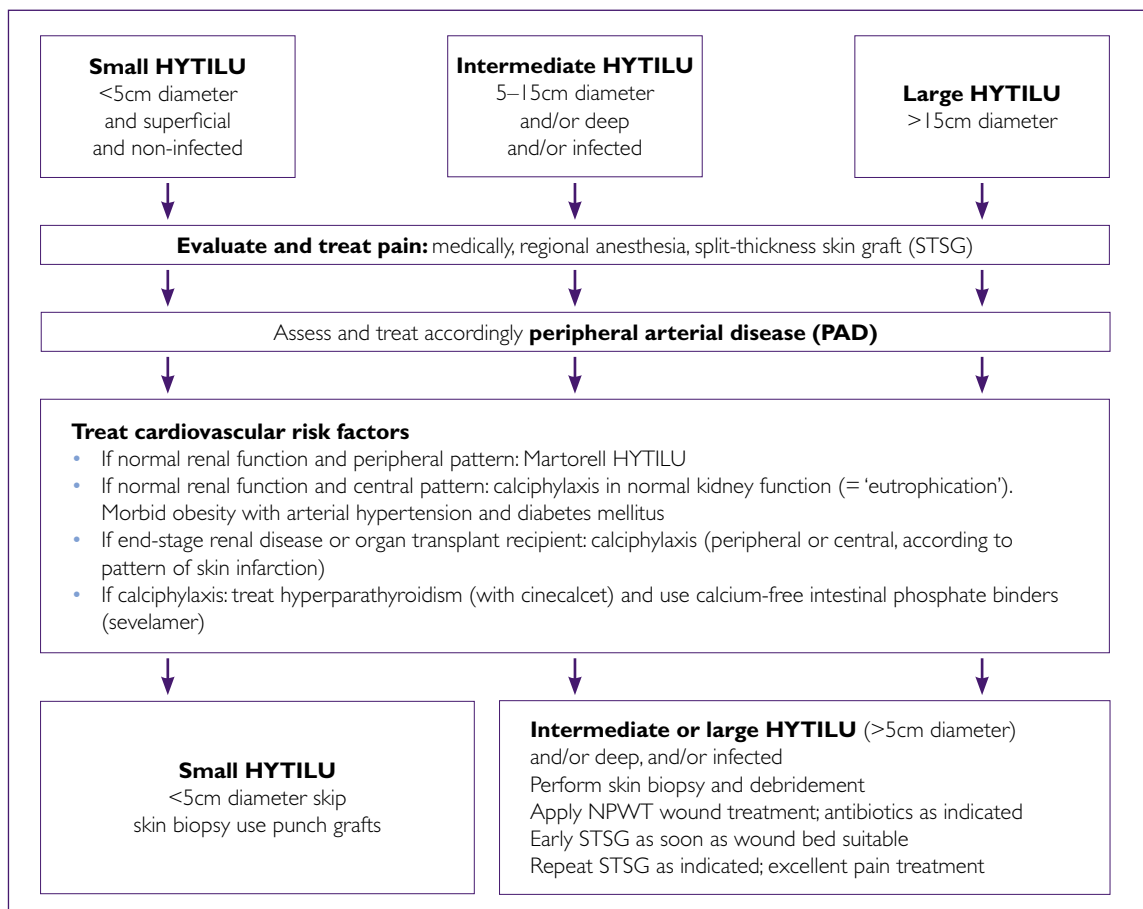


Fig 19. Treatment algorithm of Martorell hypertensive ischemic leg ulcer and calciphylaxis

It is important to embed the whole spindle shape biopsy (Fig 18) without any transverse dissections, so that histology shows a representative tissue profile of the diseased area and sampling error can be reasonably excluded. A small portion of the spindle end that has healthy surrounding skin should be dissected for direct immunofluorescence where available.

Treatment

General considerations

Treatment of calciphylaxis ± ESRD and of Martorell HYTILU (Fig 19) is based on the elimination of risk

factors (control of hypertension and diabetes, stop of vitamin K antagonists),^{121,138} and optimisation of the bone and calcium phosphate metabolism in 'classical' calciphylaxis in ESRD. This includes the use of cinacalcet,^{127,139} a direct calcimimetic agent which downregulates secondary hyperparathyroidism, the avoidance of vitamin D and calcium substitutes and of calcium-based intestinal phosphate binders.¹⁰⁴ Vitamin K1 and K2 supplementation may improve vascular calcification too.^{104,115,140}

In calciphylaxis ± ESRD the use of sodium thiosulfate as 25g in 100ml short infusion in the last 30–60 minutes of dialysis has been

proven beneficial in larger case series. RCTs are underway investigating treatment outcomes in calciphylaxis.^{104,141} In extensive cases of Martorell HYTILU use sodium thiosulfate (10g/100ml solution, 3x weekly) as well. This recommendation, however, is not based on scientific data. Sodium thiosulfate has antioxidant and vasodilatory properties and inhibits adipocyte calcification and calcification of vascular smooth-muscle cells.^{142,143} Bisphosphonates have shown efficacy in case series of 'classical' calciphylaxis in ESRD.¹³³

Patients with small forms of Martorell HYTILU benefit from minor debridement followed by immediate punch grafting.^{101,114,144,145}

Wound surgery

In patients with extensive forms of Martorell HYTILU, several case series have shown more rapid recovery when wound surgery, NPWT and early skin grafts (punch grafts (Fig 20) or split-thickness skin grafts (Fig 21 and 22) have been used.^{103,112,117,144,146} These patients mostly require antibiotic treatment to avoid local infections and sepsis.¹⁰³ The role of surgery in patients with central calciphylaxis ± ESRD is not established and has to be determined depending on the individual situations.

It is important to familiarise physicians and wound experts with the clinical appearance and pathology of Martorell HYTILU and calciphylaxis in order to offer these extremely suffering patients an optimal, straight-forward treatment.

Conclusions and recommendations

Similarity of the clinical patterns of skin necrosis and the histological pattern of ischaemic subcutaneous arteriolosclerosis suggest a common pathophysiology of (A) Martorell HYTILU, (B) distal calciphylaxis in ESRD, (C) central calciphylaxis in ESRD, and (D)

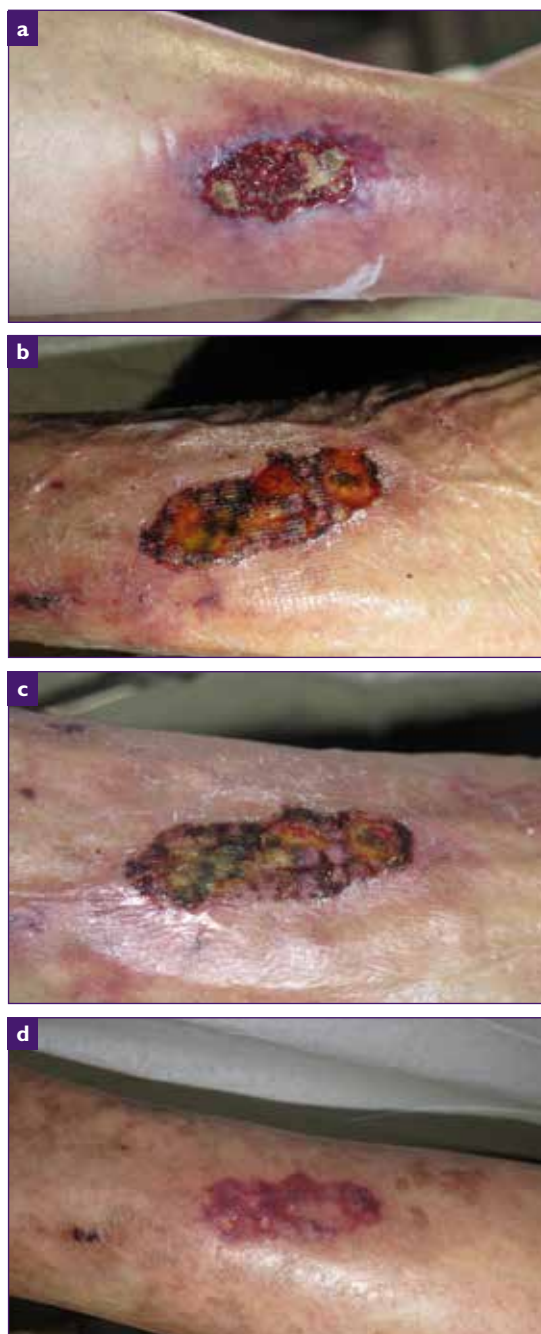


Fig 20. Martorell hypertensive ischemic leg ulcer before punch grafting (a). Same wound, day 14 after punch graft; reduction of pain (VAS 9-10 to 2-3)(b). Same wound, day 22 after punch graft (c). Same wound healed, day 58 after punch graft (d). All pictures by Elena Conde Montero

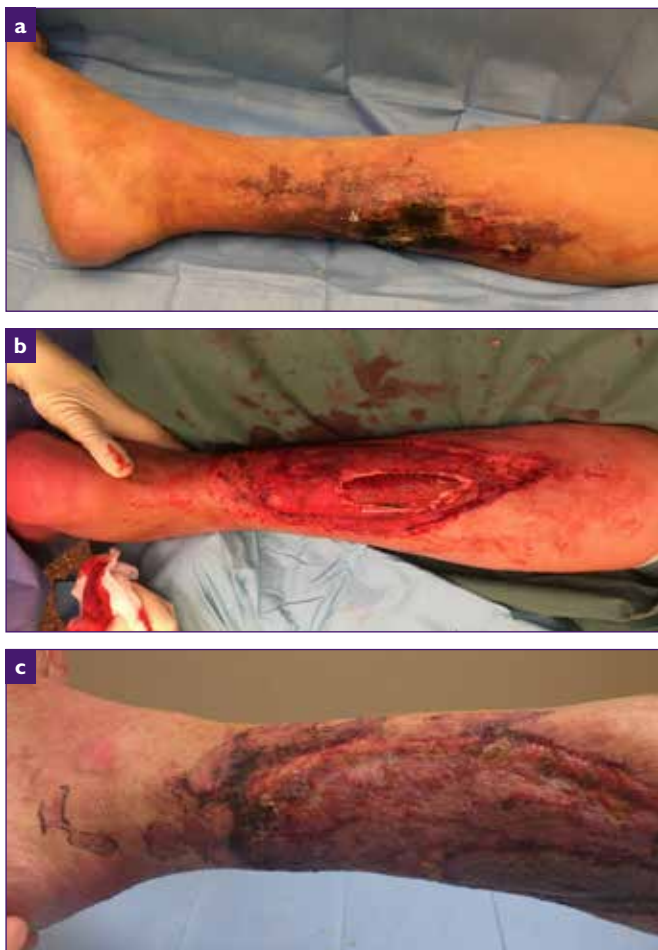

Fig 21. Martorell HYTILU laterodorsal skin infarction, large area of livedo (a). NN, m, Martorell HYTILU Inpatient treatment with necrosectomy and NPWT (b). NN, m, Martorell hypertensive ischaemic leg ulcer: Initial take of split-thickness skin graft, at week three postoperatively (c). All pictures by Jürg Hafner.

(central) calciphylaxis in normal renal function ('eutrophication' in morbid obesity). These four entities share a common histopathology (stenotic arteriolosclerosis ± miniaturised Mönckeberg arteriolosclerosis, ± intimal hyperplasia) and clinical pattern (ischaemic skin infarction).

These features suggest a partly common pathophysiology (risk factors such as hypertension, diabetes, vitamin K antagonist

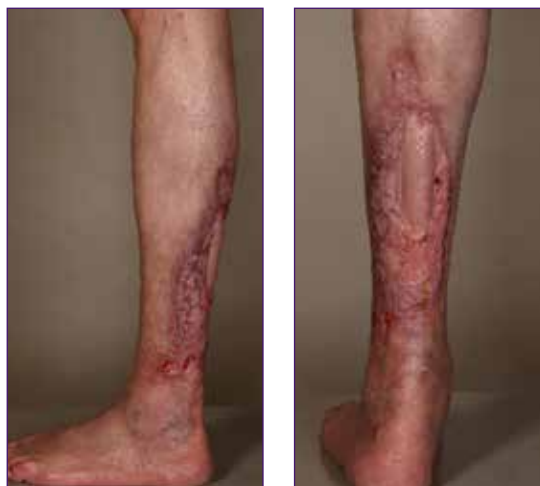

Fig 22. Martorell hypertensive ischaemic leg ulcer: Further course after a one stage of split-thickness skin graft, five months. Pictures by Jürg Hafner.

medication, and disturbed bone and calcium phosphate metabolism in 'classical' calciphylaxis in ESRD lead to stenotic arteriolosclerosis and eventually to skin infarctions and acral gangrene).

Martorell HYTILU must not be confounded with PG: The therapeutic approach is completely different. Patients with Martorell HYTILU require wound surgery and early skin grafts. Immunosuppression for erroneously diagnosed PG can become deleterious.

As in any chronic wound of the lower extremities, PAD should be ruled out and treated accordingly (eg with PTA), if present.

Confirmation of diagnosis with a long (3–6cm) and narrow (4–5mm) spindle shape biopsy may be unnecessary in patients with small forms of clinically typical Martorell HYTILU, but is highly recommended in all cases of diagnostic doubt or when major wound surgery is required.

Small skin ulcers (<5cm diameter) of Martorell HYTILU or calciphylaxis, respectively, can heal under conservative measures alone or with minor

debridement and punch grafts. Intermediate skin ulcers (<10cm diameter) mostly require necrosectomy, negative pressure wound treatment and split skin grafts. Patients with large (>10cm diameter) or extensive skin ulcers may benefit from intravenous sodium thiosulfate (10g/100ml short infusion, 3x per week).

Skin grafts should be applied precociously, even when the recipient wound bed does not expose suitable granulation. Antibiotic therapy is often required since many skin ulcers from Martorell HYTILU or calciphylaxis, respectively, become critically colonised or overtly infected in the course of necrosis progression.

Skin grafts can dramatically decrease the excruciating pain that many patients with Martorell HYTILU or calciphylaxis, respectively, have to suffer. In most instances they are the best 'pain killers'.

The take of skin grafts is often optimal in the centre, where it adheres to exposed vital fascia,

and hampered along the margins, where it should connect with necrobiotic subcutis. The polycyclic skin infarctions can become progressive along the borders and often require serial skin grafts until some smaller and more superficial wound remnants can be left to secondary wound healing.

Future perspectives

The sensitivity and specificity of the histopathologic finding of subcutaneous arteriolosclerosis needs to be investigated in a larger prospective controlled study. Arteriolosclerosis may be a systemic condition. The question of organ involvement should be further examined. Future research should focus on the pathophysiology, risk factors and protective mechanisms of hypertensive, but also diabetic, and renal arteriolosclerosis with and without calcification, and on the role of the striking inflammation—primary or secondary — that can be observed in and around the skin infarctions caused by subcutaneous arteriolosclerosis. The empirically recommended treatment measures need to be confirmed by randomised controlled clinical studies.

6. Hidradenitis suppurativa

The disease was described for the first time by Velpeau in 1839.¹⁴⁷ Hidradenitis suppurativa (HS) is an inflammatory disease which primarily affects the hair follicles of apocrine gland bearing skin, in other words, the perigenital skin and axillae, with recurrent lesions. The lesions consist of inflamed or non-inflamed nodules, abscesses and draining or non-draining tunnels (Fig 23). In more progressed stages of the disease scarring is prominent.^{148,149}

The lesions cause pain, discomfort and disfigurement. Occasionally HS appears in a syndromic form with acne, arthritis and PG in the PASH or PA-PASH syndromes.¹⁵⁰ Recently, substantial comorbidities have been linked to the disease, associated with an increased overall mortality including completed suicides.^{151,152} This suggests that HS has a systemic effect and may be seen as a more general inflammatory disease.¹⁴⁸

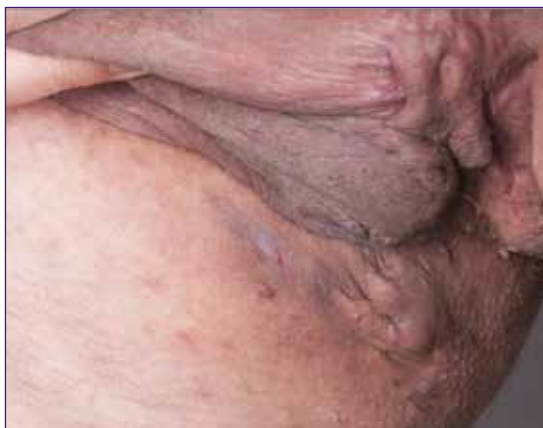

Fig 23. Severe case of hidradenitis suppurativa. Picture by Gregor Jemec.

The prevalence of the disease is reported from 0.05–4% of the population and the estimates appear to depend not only on the population sampled but also on the methodology used.¹⁵³ Registry-based studies generally report lower prevalence than self-reported data or physical examination suggesting selection bias. This is further supported by the observation that patients globally experience a clinically significant delay in diagnosis.¹⁵⁴ HS appears to exert a major life course influence on patients as a group, as it appears associated with poorer socioeconomic characteristics such as education, income and social class.^{155,156}

The concept of HS as a disease of wound healing

Chronic lesions of HS are characterised by a mix of inflammation and tissue damage in the shape of scars, tunnels and occasionally hypertrophic granulation tissue extruding from the lesions and prompting the hypothesis that HS may be a disease of wound healing.¹⁵⁷

The aetiology of the HS remains largely unknown, but it is speculated that an aberrant immune response to changes in the follicular microbiota may play a role. The pathogenesis involves the release of pro-inflammatory cytokines such as TNF and IL-17, as well as anti-inflammatory cytokines such as IL-10.^{158,159} Morphologically, the pathogenesis involves initial preclinical lesions consisting of a perifollicular lymphocytic infiltrate surrounding biofilm-depleted

follicles.^{160,161} In later stages of the disease where chronic lesions predominate, a shift towards an infiltrate consisting of neutrophils and mast cells is seen surrounding chronic tunnels containing abundant biofilm.^{162,163} At this stage metalloproteinase (MMP)-2 is also expressed in the lesions indicating cell-migration associated with wound healing.¹⁶⁴

Use of dressings in management of HS

Treatment of HS should be multimodal and consists of adjuvant therapy (lifestyle interventions), medical and surgical treatment, ideally provided in parallel rather than sequentially.¹⁶⁵ Life style interventions include information about healthy diet, weight loss, exercise and smoking cessation. Dressings provide an important adjuvant therapy in the management of HS.^{166,167}

The aim of medical treatment in HS is to reduce disease progression and inflammation, thereby reducing pain and suppuration over time. Studies have shown that chronic or recurrent and unpredictable suppuration from lesions is a major contributor to the significantly reduced Health Related Quality of Life (HRQoL) of HS.^{168,169} This involves two components: smell and seeping. Although not always clinically evident, fear of malodorous discharge from lesions is an important factor in the reduced HRQoL of the patients. In addition patients often worry about discharge seeping through clothing and leaving visible marks not only on the patients

but also on chair and other furniture. Both these fears are in principle manageable by the use of appropriate bandaging, the challenge being that most bandages are developed for use on plane or convex surfaces, whereas HS predominantly affects concave surfaces. In addition the absorptive ability, anti-odorous ability and wearer comfort play a role. Soft and absorbent dressings with a silicone-based adhesive to minimise trauma to the skin are generally useful, although the actual design and price of the products restrict their use. The design generally requires very careful placing of the dressing, which may be difficult in view of the sites involved, and the price often prohibitive. Many patients therefore resort to using sanitary pads, rags or kitchen towels.

Topical medical treatment is most suitable for either very mild Hurley stage 1 disease or single lesions. For mild disease an early trial has suggested that topical clindamycin may be beneficial, while single lesions have been successfully treated with 0.15% resorcinol.¹⁶⁵ Systemic medical treatment is primarily using antibiotics and/or immunosuppressants. The antibiotics recommended by current guidelines are primarily tetracycline-type and rifampicin, and it is thought that the main effect is immunomodulatory rather than antibacterial. Evidence grade is however comparatively low for antibiotic therapy of HS. Better evidence is available for frank immunosuppressive therapy using biologics, and particular TNF blockers (adalimumab and infliximab), but also IL-1 inhibitors (anakinra) and IL-12/23 inhibitors.¹⁶⁵

Ideally the symptoms can be controlled by medical treatment, but because HS is associated with tissue damage, residual chronic lesions may require surgical intervention. The aim of surgical treatment in HS is the reduction and amelioration of existing tissue damage, as exemplified by excision of chronic scarred lesions.¹⁶⁵ Dressings are therefore also important to the management of treatment related wounds.

The least invasive surgical procedure is the so-called de-roofing of tunnels, which involved literally removing the roof of HS tunnels.¹⁷⁰ The procedure exposes the immature epithelial lining of chronic HS tunnels to the surrounding environment and therefore only requires short-term dressing using a mildly absorbing non-adherent dressing that provides a local environment conducive to the maturation of the epithelium.

In contrast, more scarred lesions require full thickness excision of skin. Primary closure of wounds is often possible for smaller lesions, but this is often associated with higher recurrence rates.¹⁶⁵ Larger lesions may be managed by the use of NPWT and skin grafts or flaps, but are also frequently left open for secondary intention healing. Similarly, lesions treated by CO₂ laser ablation are left for secondary intention healing. Studies suggest that this 'non-surgical' approach is well accepted by HS patients and generally a safe and effective technique.^{171,172} Healing

times are however long and may be modified by late skin grafting after either partial closure of large defects or after wound preparation using negative pressure.¹⁷³ General guidelines on the management of large tissue defects apply to these postoperative wounds.

Conclusion and recommendations

Wound care forms a mainstay of HS management, both in the context of adjuvant therapy dealing with chronic disease-related problems such as drainage or hypergranulation, as well as following surgery. The use of dressings to manage spontaneous drainage from lesions is particularly helpful to patients as it provides empowerment and offers realistic possibilities of self-help. In contrast, postoperative wound care initially falls more within the realm of traditional health care using established paradigms and treatment algorithms. In either case, there is however a challenge to find suitable dressing materials, as the disease occurs in concave areas of the body while most bandages are designed for application on plane or convex areas. In the context of wound dressings, the HS patients therefore regularly experience an unmet treatment need. It is recommended that more appropriate geometric design of existing dressings is developed to suit this underserved group of patients.

7. Malignant wounds

The prevalence of malignant wounds in chronic leg ulcers is around 2–4%.^{174–177}

This number varies according to the different types of medical facilities and seems to be highest in tertiary dermatological leg ulcer centres. One prospective multicentre study in which all included patients with non-healing chronic leg ulcers were biopsied, showed a prevalence as high as 10.4%.¹⁷⁸ Many skin cancers presenting as chronic leg ulcers might be unrecognised. Thus it is important to identify these wounds as neoplastic since the treatment is different compared with vascular wounds and a cure of these wounds can usually not be achieved by conservative treatment.

Aetiology and pathogenesis

Malignant wounds can be subdivided into primary ulcerating skin tumours arising in normal skin and secondary ulcerating skin tumours that develop in chronic leg ulcers, burn scars or osteomyelitis sinuses. Primary malignant wounds are much more common than secondary malignant wounds. The group of primary malignant wounds on the leg comprises especially basal cell carcinomas (BCC) and squamous cell carcinomas (SCC). Rarely, other tumour entities like malignant melanoma, malignant vascular tumours, cutaneous lymphomas, Merkel cell carcinoma (primary neuroendocrine carcinoma of the skin) sarcomas, adnexal tumours and skin metastases are found as a cause of chronic leg ulcers (Table 9).

BCCs and SCCs are summarised under the term non-melanoma skin cancer (NMSC). Together,

they represent the most frequently observed malignancy in Caucasians.^{179–181} NMSC occurs worldwide in all races. People with fair skin and red hair (Fitzpatrick skin type 1) have the highest prevalence rates. Besides genetic predisposition and age, the lifetime cumulative UV-light exposure and longstanding immunosuppression are important risk factors.^{182–185} NMSCs are located on the head and neck region in 60–80% of cases and develop on the lower extremities infrequently.^{186,187} It has long been discussed if chronic venous insufficiency is a risk factor for the development of NMSC, especially for BCCs, but it is not clear if there is a true association or a coincidence.^{177,188–190} Concerning the frequency and types of skin tumours found in leg ulcers, data are contradictory. Depending on the published series, either BCC or SCC were predominant.^{175,177,178}

Table 9. Aetiologies for malignant ulcers

Aetiologies for malignant ulcers	
Frequent aetiologies for malignant ulcers	Basal cell carcinomas BCC Squamous cell carcinomas (SCC)
Less frequent aetiologies for malignant ulcers	Malignant melanoma Malignant vascular tumours (eg Kaposi sarcoma, angiosarcoma) Cutaneous lymphomas Merkel cell carcinoma Malignant adnexal tumours Sarcomas Cutaneous metastases Secondary ulcerating skin tumours (Marjolin ulcers)

Secondary ulcerating skin tumours are very uncommon, especially in chronic leg ulcers. In a large Swedish retrospective analysis of 10,913 venous leg ulcer (VLU) patients, only 17 patients (0.15%) were detected to have developed a transformation into a secondary malignant ulcer.¹⁹¹ More commonly, secondary malignant ulcers are found in burn scars and osteomyelitis sinuses.¹⁹² All of these ulcers are called Marjolin ulcers, named after the French surgeon Jean Nicolas Marjolin who described the malignant transformation in long lasting wounds and scars in the 19th century (Fig 24).¹⁹³

The latency period of wounds or scars before the development of a malignancy is usually more than 10 years.^{191,194} Series with latency periods of 25–27 years have been described.^{191,195,196} These secondary tumours are most frequently SCCs

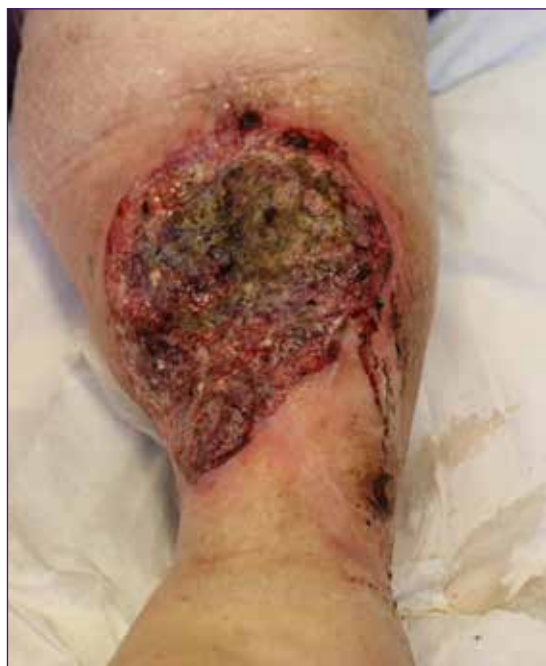

Fig 24. A 74-year-old woman with a previous history of venous leg ulcer. She was diagnosed a squamous cell carcinoma appearing as an ulcer in the left leg. Picture by Kirsi Isoherranen

but other tumours including BCCs, developing on chronic leg ulcers have been described as well.^{188,190,194,196,197} There are a number of hypotheses on the pathogenesis of SCCs and BCCs that develop in chronic wounds, including the chronic inflammation of chronic venous insufficiency. However, a clear differentiation between primary and secondary malignant wounds is difficult and cannot always be achieved, unless the ulcer development and course have been precisely documented including repeated biopsies that show a change from a benign wound to a malignant wound.¹⁸⁹

Clinical presentation

The clinical presentation of malignant wounds differs widely (Fig 25). In fact, a malignant wound can look like any other cause of chronic leg ulcers, making it difficult to establish the correct clinical diagnosis. The following factors and signs should raise the suspicion for a malignant wound: atypical ulcer location that is incompatible with the typical locations of the common vascular wounds and atypical ulcer appearance with excessive granulation tissue of the wound bed and especially the wound edges¹⁷⁸. Less specific signs are irregular wound borders, wound odour, increased wound pain and bleeding of the wound. Furthermore, a malignant wound and especially a secondary malignant wound should be expected

Table 10. Clinical hints for suspecting malignant wounds

Clinical hints for suspecting malignant wounds	
Common	Excessive granulation tissue of the wound bed and the wound edges Atypical ulcer location Change in appearance of a long lasting ulcer (enlarging size, hypertrophic wound edges)
Less specific	Irregular wound borders Wound odour Increasing wound pain Bleeding fragile tissue

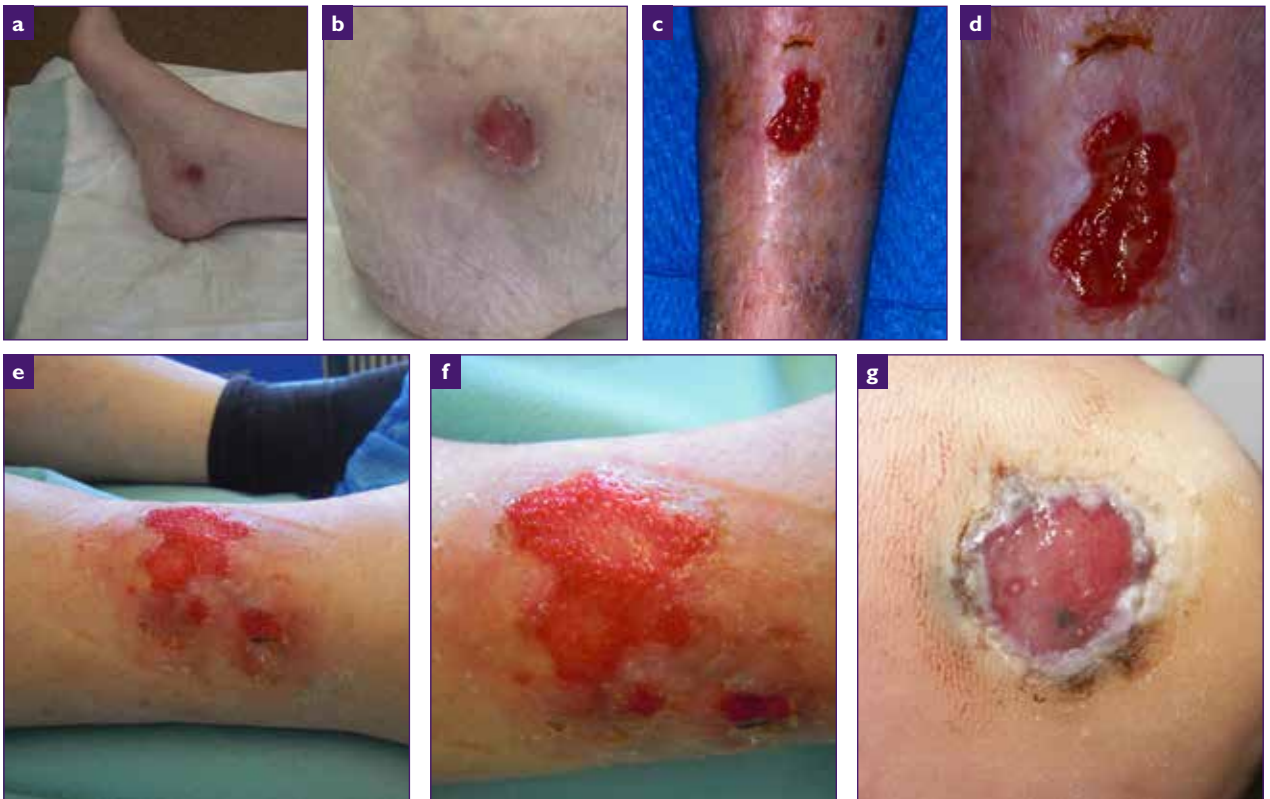

Fig 25. A 92-year-old female with ulcerating basal cell carcinoma on the medial ankle (a), close-up (b). A 91-year-old male with ulcerating squamous cell carcinoma on the anterior lower leg (c), close-up (d). A 81-year-old female with ulcerating amelanotic malignant melanoma on the anterolateral lower leg (e), close-up (f). An 83-year-old male patient with ulcerating malignant melanoma on the heel (g). All pictures by Stephan Nobbe

if there is a change in appearance of a long lasting ulcer (Table 10).¹⁹⁶

Some malignant wounds show none of these criteria. Generally all malignant wounds have one aspect in common: they do not heal with standard treatment that is commonly used for chronic (venous) wounds, such as compression therapy and wound dressings or off-loading for neuropathic ulcers. Clinicians should always be suspicious and consider the possibility of malignancy if there is a delay in wound healing despite appropriate treatment. If this is the case or if one or more of the above-mentioned criteria exist, further diagnostics should be

initiated and the patient should be referred for specialist advice.

Diagnostics and staging

The most important step for diagnosing a malignant wound is a biopsy for histological analysis.

A wound biopsy can be performed either as a narrow and deep wedge-shaped excision or as a 5–6mm punch biopsy and is usually done under local anaesthesia. It is generally a safe procedure, and the subsequent wound usually heal within a few weeks with no delay in wound healing.¹⁹⁸ Performing at least two biopsies on different areas of the wound (wound edge and wound bed) to avoid

the risk of false-negative single biopsies is highly recommended.^{177,178} Particularly the wound edge, including epithelium should not be missed in the biopsy because on occasion malignant histological

changes are only found in the wound edge of the ulcer.¹⁹⁹ Repeated biopsies should be considered in case of previous negative biopsies but unchanged suspicious appearance of the wound. This is

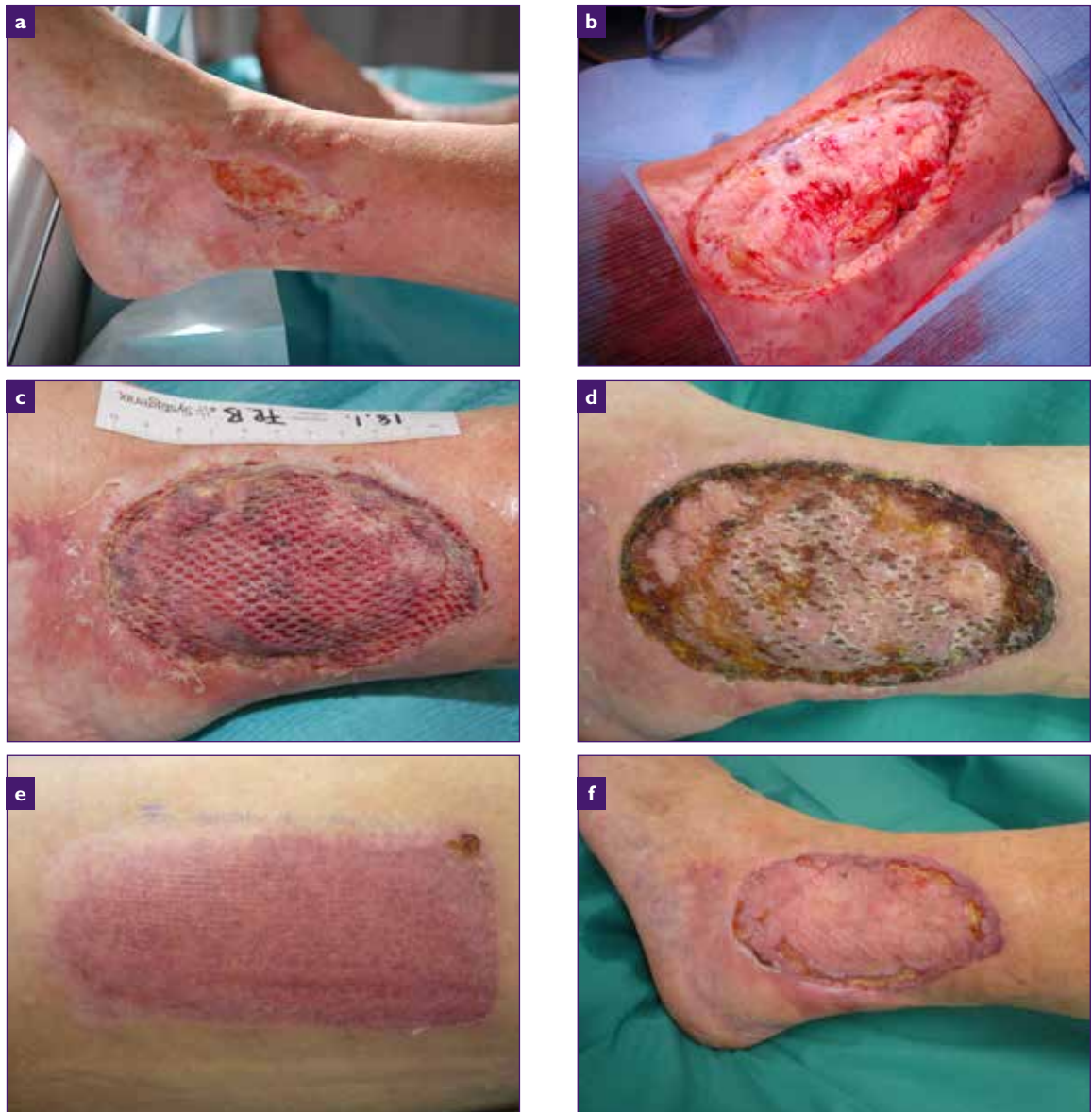

Fig 26. A 59-year-old female patient with squamous cell carcinoma secondary to a chronic vascular ulcer on the lateral ankle (a). Excision of tumour with 1.5cm safety margin (b). Follow-up 1 week after transplantation with meshed split-thickness skin graft (STSG) from the lateral thigh (c). Follow-up three weeks after STSG (d) Donor site on the lateral thigh three weeks after harvesting of STSG (e). Follow-up two month after STSG (f). All pictures courtesy of Jürg Hafner.

especially important when the development of secondary malignant wounds cannot be ruled out.

When the diagnosis of a malignant wound is established, staging examinations to detect potential lymph node or organ involvement should be considered. The extent of the staging depends on the tumour entity, tumour size and location, histologic features and patient characteristics (eg immunosuppressive medications). For BCCs confined to the skin, a thorough clinical examination is most important, and radiologic imaging is usually not necessary. Radiologic imaging can be useful to detect the extent of tissue invasion (computed tomography for bone assessment and magnetic resonance imaging for soft tissue and nerve examination) and to detect lymph node metastases (ultrasonography or computed tomography). For high-risk SCCs (tumour diameter >2cm, tumour thickness >4mm, poor histological tumour differentiation, perineural infiltration, Marjolin ulcer), the examination with ultrasonography or computed tomography of the draining lymph node basins is recommended.^{184,200,201}

Treatment and follow-up

Treatment for localised malignant wounds is primarily surgical. Micrographic surgery reduces the risk of tumour recurrence and can usually be performed as classic Mohs surgery with histologic control of the entire excision margin in frozen sections. The specimen has to be embedded with a special technique in order to visualise the entire resection margin and the histologic slides are read by the dermatologist. For larger tumours and if Mohs surgery is not available, histologic margin control can be performed on paraffin sections and the defect closure delayed by a few days. Aggressive tumours, (eg secondary malignant tumours with histologically undifferentiated appearance) should be excised with a safety margin of several cms and in

case of bone involvement, these tumours even require amputation.²⁰²

For defect closure on the lower leg, STSG from the lateral thigh to the wound is often performed because the skin in region around the ankle is tight and difficult to mobilise (Fig 26).

This technique is relatively simple and safe and can be performed in larger defects. Furthermore and importantly, a tumour relapse is usually detected earlier in clinical follow-up examinations in wounds closed by skin grafts compared with flap reconstructions. However, skin grafts on the lower leg tend to heal slowly especially if there is concomitant venous or arterial disease, and typically result in depressed, atrophic or hypopigmented scars. Alternative techniques for surgical wound closure are local skin flaps for wounds <4cm in diameter²⁰³⁻²⁰⁶ and fasciocutaneous flaps^{207,208} or axial flaps^{208,209} for larger wounds.

The use of radiotherapy for treatment can be an option for some tumour entities and especially as for palliative treatment. It has to be mentioned that poor wound healing after radiotherapy of malignant skin lesions on the lower leg was described in one series in a third of patients and was related to old age of patients, the diameter of the radiotherapy field and the dose and energy of radiotherapy used.²¹⁰ Alternative treatment modalities for malignant tumours on the lower leg are, in selected cases and depending on the entity and the tumour-stage, electrochemotherapy, cryotherapy, intralesional interferon, photodynamic therapy or topical chemotherapy.

In locally advanced and surgically non-resectable BCCs, radiotherapy or systemic therapy with a hedgehog-inhibitor (vismodegib) can be a therapeutic option. For advanced and metastasised SCCs, radiotherapy and systemic therapies

(chemotherapeutic agents, targeted therapies, and immunotherapies) are available.

All skin tumour patients should receive follow-up consultations to detect recurrences or further skin tumours at different sites. If recurrences of SCCs occur, they appear in >75% within two years after the initial diagnosis.^{211,212} Patients with BCCs and low-risk SCCs should be seen every six months during the first two years, followed by annual consultations for clinical skin and lymph node examinations. In case of high-risk SCC, follow-up visits may be considered every three months in combination with repeated imaging (ultrasonic or computed tomography examinations of the lymph nodes, MRI in cases of nerve invasion) every six months for two years.¹⁸⁴

Prognosis

The prognosis of malignant wounds depends on the underlying tumour entity and if the wound was a primary or secondary tumour. Primary basal cell carcinomas and squamous cell carcinomas are usually cured after complete excision,¹⁷⁷ if they are recognised as tumours early and are treated accordingly. Ulcerating melanomas and high-risk SCCs, e.g. secondary malignant wounds (Marjolin ulcers) have a less favourable prognosis. They tend

to be more aggressive and have a relevant metastatic rate. The mortality rate of patients with a Marjolin ulcer was described as high as 37% in one study.¹⁹⁶

Conclusions

Unfortunately malignant wounds are not uncommon and most health professionals who treat patients with chronic leg ulcers will experience patients with these types of wounds. In most cases malignant wounds on the leg are caused by ulcerating skin tumours that arise on non-ulcerated skin, especially BCCs and SCCs. A correct diagnosis can be achieved by performing one or several wound biopsies for histological analysis. Treatment for malignant wounds is usually surgical with complete excision of the tumour that leads to complete healing in most cases.

Recommendations

Wound care professionals should be suspicious and think of a malignant wound if the clinical appearance or the location of the wound is atypical or if there is insufficient healing tendency despite assumed appropriate treatment. If this is the case, wound biopsies (see Ch. 11 Histology of atypical wounds) should always be performed for further diagnostics.

8. Artefactual ulcers

Factitious ulcers are a form of dermatitis artefacta and they can represent a real challenge for the clinician in terms of diagnostics and treatment. Dermatitis artefacta can be defined as the deliberate and conscious production of self-inflicted lesions, such as ulcers, to satisfy an unconscious psychological or emotional need.²¹³ This disorder is predominantly seen in women with underlying psychiatric diagnoses and is exacerbated frequently during periods of increased stress. Usually the patient does not admit self-inflicting the lesions and thus misdiagnosis with other diseases is frequent.²¹⁴ As there is a lack of specific diagnostic characteristics, it is usually a diagnosis of exclusion.

Incidence and aetiology

Dermatitis artefacta may occur at any age, with the highest incidence being in the late teens or early twenties and with a female-to-male ratios varying from 3:1 to 20:1.²¹⁵ Factitious ulcers appear in mysterious ways and usually the patient denies all responsibilities for them. The ulcers often

reflect deeply buried psychological distresses.²¹⁶ The patient's initial goal is to satisfy an internal emotional need — the need to be taken care of and to draw family members' attention and hospital admission.^{217,218} A common feature is also a close connection of either the patient or a family member with health-care field²¹⁵. There may be also a history of physical or sexual abuse.²¹⁹ The majority of patients with long-standing dermatitis artefacta have border-line personality disorders. It is also important to note that chronic dermatitis artefacta is a disorder of body image and may be associated with eating disorders.²²⁰ Munchausen's syndrome-by-proxy is similar, except the mother is the patient while the child who presents with lesions is too afraid to speak²¹⁵.

Clinical presentation

The clinical morphology of factitious ulcers is variably depending on the method of injury, but typically they display geometric or other unusual patterns, with sharply demarcated edges and spare anatomic areas that are difficult to reach (Fig 27 and

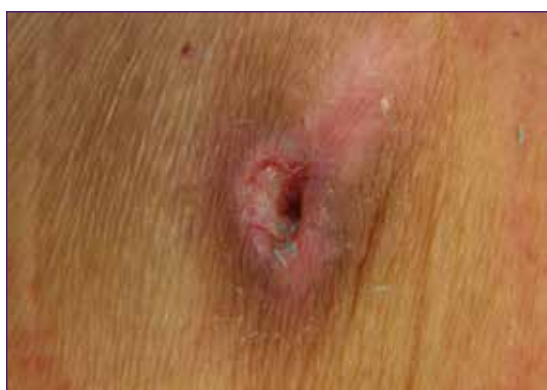

Fig 27. An artefactual ulcer in the abdomen region. Picture by Kirsi Isoherranen.

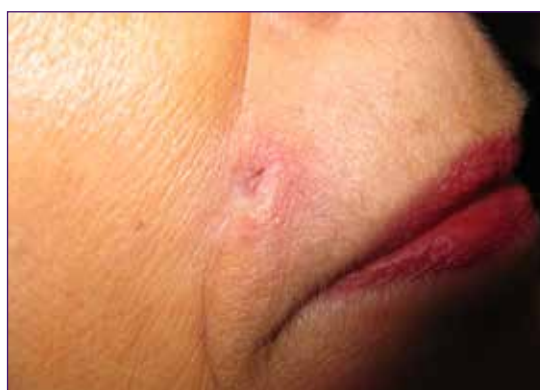

Fig 28. An artefactual ulcer in the face region. Picture by Kirsi Isoherranen.

28).²²¹ Common sites are the face, upper trunk and extremities. The lesions appear fully formed, all at the same stage of development. This lack of evolutionary changes has been termed the 'hollow' history and is characteristic for dermatitis artefacta.²²²

Diagnosics

Factitious ulcers are usually a diagnosis by exclusion. First of all, it is important to rule out the most common aetiologies of ulcers: arterial, venous, mixed, pressure or diabetic ulcers. Secondly, other atypical wounds, such as vasculitis and PG, are ruled out and usually a biopsy is needed. Unfortunately, the microscopic findings in suspected factitious ulcers are often non-specific, but there are reports indicating that the presence of multinucleated keratinocytes often comprised of more than five nuclei.²²³⁻²²⁶ The clinician may also suspect factitious ulcers by the strange history, presentation and morphology.

Treatment

Standard wound management, such as gentle debridement and wound dressings all have their place in the treatment. Occlusive dressings have been used to prevent further self-mutilation, however their use is unlikely to prevent the patient transferring their activity to another area of the skin.²¹⁵ The most important treatment is psychiatric and psychological therapy. If a sufficiently supportive empathetic non-confrontational environment can be established, a psychiatric referral may be possible. Ideally, a joint consultation with a dermatologist and a psychiatrist should be organised which enables

the psychiatric evaluation to proceed gradually. Psychological treatment aims to strengthen the patient's ability to recognise hidden stressors leading to harmful behaviour and to provide tools to avoid it. Cognitive behavioural therapy and psychotherapy can be helpful if the patient is willing enough to receive help.²²⁷

In case the patient is strongly opposed to being referred for a psychological/psychiatric assessment, it is recommended that the health professional prescribes a psychotropic drug such as selective serotonin reuptake inhibitor (SSRI), buspirone or an atypical antipsychotic, such as risperidone or olanzapine.²¹⁵ It is also recommended to see the patient at frequent intervals and not to discharge the patient.²²⁸ Preferably, after starting the medication, the patient would agree psychiatric referral even if first denied.

Conclusions and recommendations

Patients with factitious ulcers can have personality disorders which make the consultation challenging. It is recommended to avoid confrontation. The best option is to create a trusting relationship and providing support so that the patient feels secure and considers the relationship to be helpful and not to threaten her/his self-esteem. The timing of discussing the diagnosis with the patient is extremely important. It is recommended that it would not be too soon in the first appointments, but also avoiding the topic too long is suboptimal. If the patient denies psychiatric referral, it is recommended that the dermatologist/other specialist prescribes psychotropic drugs.

9. Ecthyma and ecthyma gangrenosum

Ecthyma is a cutaneous bacterial infection that extends into the dermis and causes skin ulceration. Consequently, it heals with scarring and it is widely considered a deeper type of impetigo.²²⁹ The term ecthyma gangrenosum (EG) is generally accepted to be reserved for the cutaneous features of *Pseudomonas aeruginosa* bacteraemia in immunocompromised patients.²³⁰ However, other bacterial and fungal aetiologies have been detected underlying the same clinical presentation,²³¹ both in immunocompromised and healthy patients. Moreover, cases associated and non-associated with bacteraemia have been described.²³² Consequently, after an exhaustive search of cases in the literature, it has been suggested that there is no need to separate *Pseudomonas aeruginosa* and non-*Pseudomonas aeruginosa* EG cases.^{137,233}

Considering that different diseases may mimic ecthyma and EG (the so-called ecthyma-like lesions), an extensive anamnesis, clinical examination and further microbiological and histological exams may be needed for diagnosis.^{229,234}

Aetiology and pathophysiology

Ecthyma is an ulcerative infectious disease and may be caused by different bacteria, mainly group A beta-haemolytic streptococci, such as *Streptococcus pyogenes*. *Staphylococcus aureus* is often concurrently isolated from purulent exudate on the ulcer and can also be the only involved bacteria. As ecthyma normally arises over skin disruptions, risk factors include arthropod bites

or stings, poor hygiene, malnutrition and tropical climate. Ecthyma is not a rare skin and soft tissue infection among international travellers and, in these cases, is commonly associated with multiple lesions and a history of arthropod bite.²²⁹

EG traditionally referred to a pathognomonic cutaneous manifestation of *Pseudomonas aeruginosa* bacteraemia that mainly affected immunocompromised patients, especially with neutropenia, underlying malignant disease (leukaemia, lymphoma) or organ transplant.²³⁰ However, during the last 40 years, several authors have suggested that other *Pseudomonas* spp. and various bacteria, such as *Aeromonas hydrophila*, *Escherichia coli*, *Klebsiella pneumoniae*, *Morgagnella Morgagni*, *Stenotrophomonas Maltophilia*, atypical mycobacteria as well as some fungi, such as *Candida* or *Fusarium* spp., could be the causal agents.^{235,236} Different species can be also found in the same lesion. Moreover, as EG may occur in immunocompetent and healthy patients, with no associated bacteraemia, it has been suggested not to be considered just as a skin manifestation of a severe systemic infection (microbial seeding through blood into the skin), but also a primary skin lesion in the site of entry or inoculation of the organism into the skin.^{137,233,235,236} In a review on 167 patients with EG, *Pseudomonas aeruginosa* was detected in 73.65% of cases, of them, only 58.5% cases with sepsis.²³³ In children, it has been reported to occur in the perineal area of healthy infants after antibiotic therapy in association with maceration of the diaper area.²³⁷ However, it is important to rule out predisposing risk factors in new-born infants.²³⁸

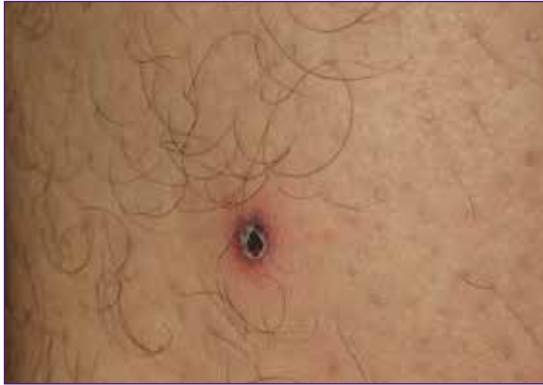

Fig 29. Necrotic crust with erythematous halo on the leg. Picture by Elena Conde Montero.

Regarding the physiopathological mechanism, microbial invasion of skin vessels results in secondary thrombosis of the arterioles, tissue oedema and epidermal separation from the dermis, which causes the typical bullous purpura and subsequent necrotic ulcer.¹³⁷

Clinical presentation

Ecthyma normally begins as a vesicle or pustule with grey-yellowish exudate that rapidly becomes a shallow punched-out ulcer with erythematoviolaceous base and necrotic crust

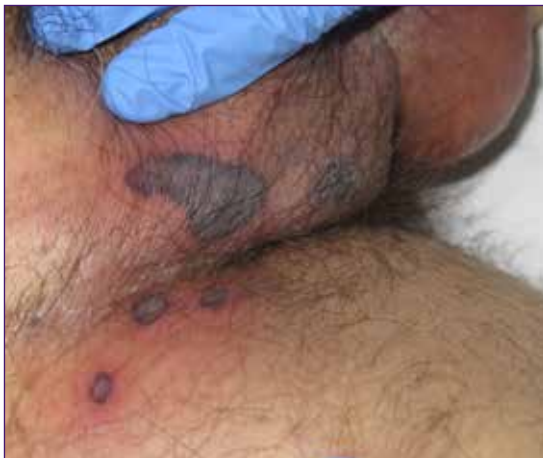

Fig 31. Palpable purpura on the groin in an immunosuppressed patient. Picture by Elena Conde Montero

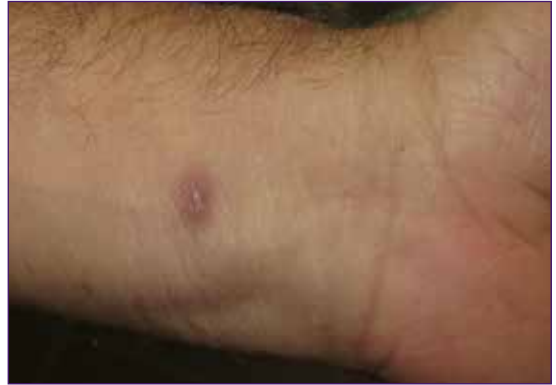

Fig 30. Post-ecthyma scar on the wrist. Picture by Elena Conde Montero.

(Fig 29). The lesions can be multiple and they are typically located on the lower extremities. Healing of these lesions implies residual scarring (Fig 30).

EG commonly presents with erythematous or purpuric macules that rapidly evolve to vesicles or nodules and subsequent ulcers with black eschar formation with a surrounding erythematous halo (Fig 31–34). Typically, initial vesicles appear on an oedematous background and coalesce to form large bullae. These bullae finally leave an ulcerated centre. This lesion progression may occur in hours.

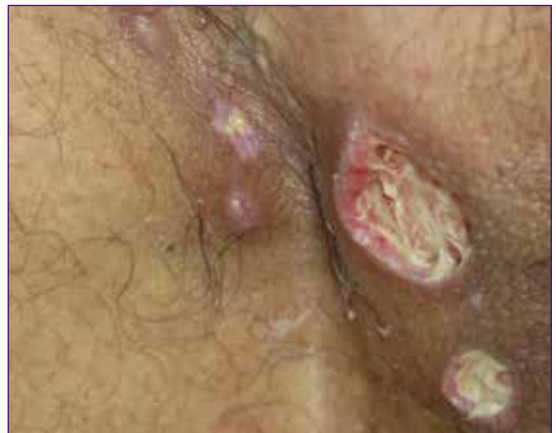

Fig 32. Rapid progression of the purpuric lesions into ulcers. Sloughy wound beds can be seen after surgical debridement of the black eschar. Picture by Elena Conde Montero

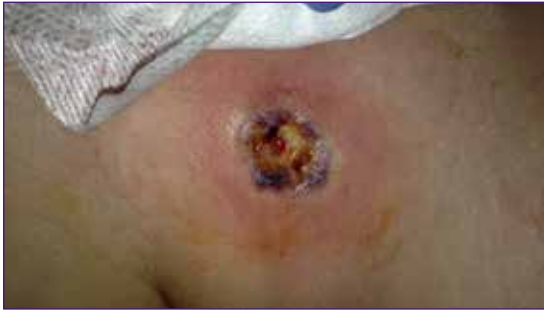

Fig 33. Rapidly growing purpuric nodule on the chest of an immunosuppressed woman. Picture by Elena Conde Montero

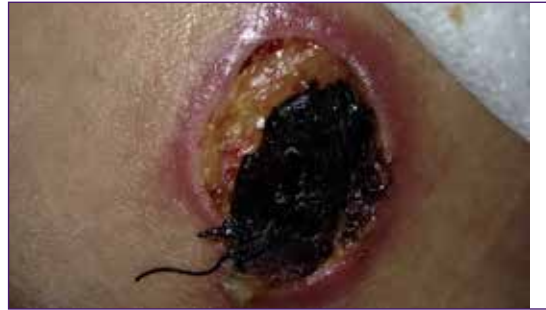

Fig 34. Fast development of an ulcer covered by black scar. Picture by Elena Conde Montero

Skin lesions can be single or widespread, which is associated with worse prognosis in immunocompromised patients²³⁹. The buttocks, perineal area and lower extremities are the main affected sites, but lesions can occur in any part of the body, such as the face,²⁴⁰ chest or neck.

Diagnosics

As the clinical appearance of ecthyma and EG may be polymorphic and similar to other dermatosis, a complete history considering the immune status of the patient, potential risk factors, and environmental or animal exposures may be clues for diagnosis. However, microbiological tests and histological exams are necessary to confirm diagnosis and rule out other diseases. Microbiological tests include blood culture and skin biopsy for tissue culture for bacteria, fungi, yeasts, and mycobacteria. Specimen processing includes the detection of bacteria by culturing, biochemical identification, and susceptibility testing.¹³⁷

A second biopsy is sent for histological exam. Histological findings will show vascular necrosis and intravascular thrombosis with a mixed inflammatory cell infiltrate²³⁰ (see Ch. 11 Histology of atypical wounds). Gram-negative bacilli may be seen in the dermis and perivascular area in cases of EG caused by these bacteria, such as *Pseudomonas aeruginosa*.²³⁰

Atypical Mycobacterium infection diagnosis requires a high index of suspicion. Culture in appropriate medium and histopathology findings, which show a granulomatous dermatitis, are essential for diagnosis. A Wood's lamp may be helpful for diagnosis, as lesions caused by *Pseudomonas aeruginosa* will show green fluorescence.²³³ Differential diagnoses should include the following entities:^{137,229,234}

- Rickettsial disease (tache noire)
- Loxoscelism
- Cutaneous anthrax
- Cutaneous leishmaniasis
- Ecthyma contagiosum (orf)
- PG
- Buruli ulcer
- Vasculitic skin ulcers
- Anticoagulant-induced skin necrosis
- Other occlusive vasculopathies, such as calciphylaxis, septic emboli, disseminated intravascular coagulation.

Treatment

Considering the broad spectrum of aetiologies in ecthyma and EG patients, we should differentiate between the specific microbiological treatment and the general topical measures for wound healing in all cases.

Therapy for patients with limited ecthyma lesions may just consist of topical antibiotics. However, for cases with wider involvement, oral antibiotics are recommended.

In the case of clinical suspicion of EG, mainly in immunocompromised patients, empiric anti-pseudomonal antibiotics after sending a sample for culture are highly recommended.^{137,233} A combination of an aminoglycoside and an anti-pseudomonal β -lactam antibiotics is commonly recommended for treatment of EG, regardless of the presence of bacteriemia.²³⁶

Some of the prognostic factors of the disease, mainly in severe cases, are the time of onset of antibiotic therapy and the patient's response to therapy.^{229,236}

The microbiological results will indicate the appropriate treatment, which may be antibiotic and/ or antifungal therapy. Intravenous anti-pseudomonal antibiotics are necessary for treatment for pseudomonal EG. In immunocompromised patients with non-pseudomonal EG, intravenous microbiological treatment should also be considered.

Once the aetiological treatment of EG has been established, the necrotising soft-tissue lesion must be locally managed. Necrotic tissue should be removed. In small lesions, both autolytic and bedside surgical debridement can be satisfactory. However, in large necrotic ulcers, aggressive surgical debridement followed by skin grafting may be necessary. The surgical approach to *Pseudomonas* and non-*Pseudomonas* cases is similar.¹³⁷

Conclusions and recommendations

The term EG is not limited to the cutaneous features of *Pseudomonas aeruginosa* bacteraemia in immunocompromised patients. Consequently, healthy patients, absence of bacteraemia or non-pseudomonal findings should not be considered exclusion criteria for EG diagnosis.

Clinical features of EG are non-specific and other ecthyma-like lesions should be considered in differential diagnosis; such as arthropod bites, anticoagulant-induced skin necrosis, PG, vasculitis or occlusive vasculopathies.

Complete anamnesis and a skin biopsy for microbiological and histological exams are essential to allow early recognition of EG.

Considering that prompt treatment is necessary to reduce mortality, especially in immunocompromised patients, early empiric anti-pseudomonal antibiotics and debridement of necrotic tissue are the key therapeutic strategy.

10. Other types of atypical wounds

In addition to the atypical wounds covered in other chapters, there are a number of atypical wounds which challenge the clinician in terms of recognition, diagnosis, management and treatment.⁷ In this chapter we describe atypical wounds associated with inflammatory, medication-related and infectious processes.

Inflammatory wounds

Ulcerative lichen planus

Lichen planus is an inflammatory skin disease.

The classical forms of lichen planus (purple, pruritic, polygonal, and papules/plaques) are easily recognised, but there are subtypes that are more uncommon.^{7,241} These subtypes include ulcerative lichen planus (ULP), which affects typically adult women. Typical features include hypertrophic, hyperkeratotic, bullous and scaly lesions on the plantar surface of the feet. Also mucosal involvement may occur²⁴¹. Along with skin manifestations there can be absence of toe nails and scarring.²⁴² Diagnosis is confirmed by biopsy, also direct immunofluorescence specimen is recommended in order to exclude LP pemphigoids. Serologic testing for hepatitis is also recommended, as hepatitis C has been associated with ULP.⁷ Treatment results can be unsatisfactory. Systemic treatments include retinoids and cyclosporine and local therapy options include UVA-1, corticosteroids and tacrolimus.^{7,241,242} In severe cases surgical excision and grafting can be considered.²⁴¹ It is also important to know that this chronic inflammatory disease may predispose to SCC, and therefore serial biopsies are recommended on ulcers resistant to treatment.^{7,243}

Ulcerative necrobiosis lipoidica

Necrobiosis lipoidica is an inflammatory disorder of the subcutaneous tissue. Traditionally it has been linked with diabetes and approximately 50–80 % of patients with necrobiosis lipoidica have diabetes.²⁴⁴ However, it is important to keep in mind that not all of necrobiosis lipoidica patients have diabetes or will have it during follow-up.²⁴⁵ Necrobiosis lipoidica typically appears as yellowish-brown, shiny annular lesions in the pretibial region of the legs in young to middle-aged women. In approximately 35% of the cases, these lesions ulcerate²⁴⁶ (Fig 35) and the ulcers are in most cases hard-to-heal. Treatment options include topical, intralesional and systemic corticosteroids; tacrolimus, cyclosporine, hydroxychloroquine, clofazimine, phototherapy, pentoxifylline as well as biologic agents as etanercept and infliximab.^{7,244} In resistant cases skin grafting is an option.²⁴⁴ Even if there is no evidence about

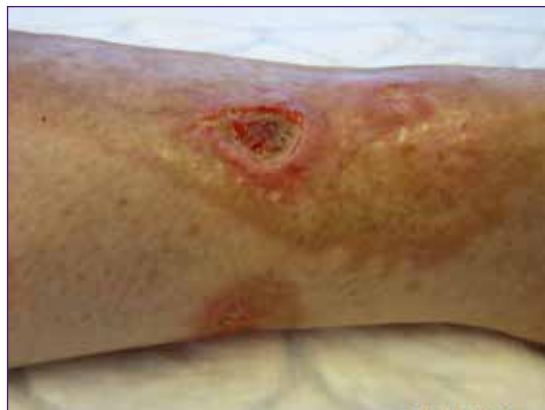

Fig 35. Ulcerating necrobiosis lipoidica. Picture by Kirsi Isoherranen.

the benefits of compression therapy in ulcerative necrobiosis lipoidica,²⁴⁷ clinical experience strongly recommends it; also in terms of prevention. As with ULP, there are also reports of SCC developing in necrobiosis lipoidica.²⁴⁸

Ulcerative panniculitis

Panniculitis is a general term for an inflammatory disorder of the subcutaneous adipose tissue. Clinically it presents as tender, sometimes ulcerating, subcutaneous nodules in the lower extremities. Different forms of panniculitis are nodular vasculitis (see Ch. 3 Vasculitides as causes of wounds), erythema nodosum, pancreatic panniculitis and α -Antitrypsin deficiency. Especially in pancreatic panniculitis there can be systemic symptoms such as fever, abdominal pain, arthritis, ascites and pleural effusions.³ Treatment depends on the specific form of panniculitis.

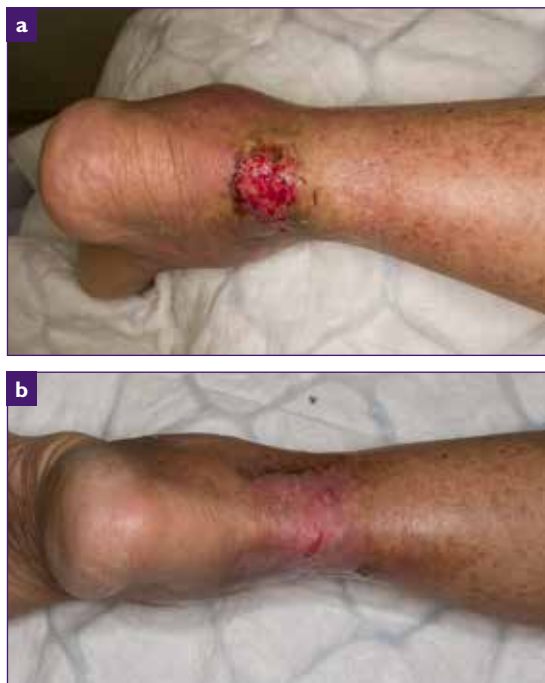

Fig 36. An ulcer caused by hydroxyurea (a). The same ulcer two months after cessation of hydroxyurea (b) and one month later the ulcer was completely healed. All pictures by Kirsi Isoherranen.

Ulcerative sarcoidosis

Sarcoidosis is an inflammatory, granulomatous inflammatory disorder affecting lungs, skin and heart. Cutaneous involvement occurs in approximately 25% of patients and of these lesions, approximately 5% ulcerate.²⁴⁹ The typical patient is a young adult black woman and lesions appear predominantly in the pretibial area of the legs. Treatment can be challenging; methotrexate, corticosteroids, anti-malarials, mycophenolate mofetil and thalidomide have been listed as treatment options.^{7,250} There are also reports of response to adalimumab.²⁵¹

Other inflammatory atypical wounds

Patients with **rheumatoid arthritis (RA)** have an increased risk of leg ulceration.²⁵² This patient group is challenging, as wounds are typically multi-aetiological. In addition of having a venous, arterial, diabetic or pressure origin an inflammatory component is often seen.⁷ RA is a well-known comorbidity in PG and vasculitis ulcers (see Ch. 5: Pyoderma gangrenosum and Ch. 6: Vasculitides as causes of wounds) and presumably vasculitic ulcers have been reported also in Felty's syndrome referring to the combination of RA, neutropenia and splenomegaly.²⁵³

Tophaceous **gout** is also known to associate with ulcers, most of which occur on the foot region.²⁵⁴ Autoimmune blistering diseases, such as **pemphigoid and pemphigus**, can also create non-healing ulcers especially in the lower leg region. **Digital ulcers associated with systemic sclerosis** may act as red flag for increased mortality,²⁵⁵ but this entity will not be covered in detail in our document.

Iatrogenic ulcerations

Hydroxyurea is a cytotoxic agent used mostly in the treatment of myelodysplastic disorders. It has been reported that it cause ulceration in nearly 10% of patients receiving continuous treatment.²⁵⁶

Ulcers typically occur after some years after initiating therapy and present as small, well-defined, bilateral and painful ulcers around the ankles (Fig 36).²⁵⁷ Withdrawal of the drug generally heals these ulcers, but advanced therapies can be used to accelerate the healing.²⁵⁸

Methotrexate therapy has been associated with a variety of cutaneous adverse effects, and cutaneous ulceration and severe epidermal necrosis are also rare side effects.^{259,260} Ulcerations are typical for psoriasis patients, with type I and type II ulcerations. Type I ulcerations occur in psoriatic plaques, whereas type II ulcerations occur in skin of patients with psoriasis with some other pathology, like venous insufficiency. The medication should be then discontinued or dose-adjusted.⁷

Both **heparin** and **coumarin** medications can cause necrosis (see Ch 4. Occlusive vasculopathy). These adverse reactions can be fatal and therefore should be diagnosed promptly.²³⁴ Typically they appear some days after starting the therapy, but there are also reports of delayed onset.²⁶¹ Diagnosis is clinical, and the lesions start as erythematous plaques and evolve into necrotic and haemorrhagic blisters or ulcers. Diagnosis prompts immediate discontinuation of coumarin or heparin, and the use of supportive fresh-frozen plasma or vitamin K in case of warfarin necrosis.²³⁴

Nicorandil, which is a commonly prescribed medication for angina, has also been reported to cause oral and anal ulceration and stopping of the medication led to healing of the ulcers.^{262,263}

Infectious ulcerations

There are a number of microorganisms that can cause ulcers. The amount of these ulcers is likely to rise in Western countries due to travelling and immigration. Treatment of these infectious ulcers

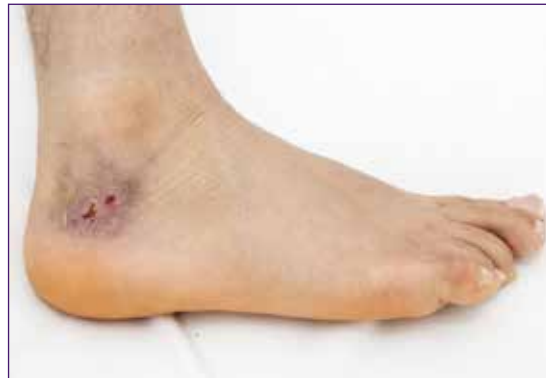

Fig 37.A 16-year-old refugee with an ulcer in the malleolar region for 6 months. PCR sampling revealed *Leishmania tropica*. Picture by Kirsi Isoherranen.

should be planned in cooperation with an internist specialised in infectious diseases.

Cutaneous leishmaniasis presents as an ulcer that can heal by itself over 3–18 months, but can also lead to severe scarring and up to 10% of cutaneous leishmaniasis cases progress to more severe manifestations (Fig 37).²⁶⁴

In **Acanthamoeba**, ulcerated nodules can be the first sign of disseminated disease in immunocompromised patients.^{7,265} **Amebiasis** is a protozoal infection that can cause clinically evident disease after months or years following exposure. Cutaneous ulcerations due to **amebiasis** occur typically perianally.^{7,266} **Mycobacteria** are also capable of causing a wide range of cutaneous manifestations, and **Buruli ulcer** is caused by **Mycobacterium ulcerans** and other related slowly growing mycobacteria. Buruli ulcer occurs mainly in the lower extremities and presents first as a painless nodule or a large indurated plaque that evolves in a period of approximately four weeks into an ulcer with undermined borders.²⁶⁷

Miscellaneous

Age-related cutaneous fragility (**dermatoporosis**)

is associated with **deep dissecting haematomas** that occur after minimal trauma. Management involves surgical evacuation of the haematoma in order to avoid larger ischaemic necrosis of the deeper subcutaneous tissues.⁷ **Trigeminal trophic syndrome** results from injury to the trigeminal nerve and the resulting dysaesthesia leads to self-mutilating

behaviour causing atypical facial ulcers.²⁶⁸ Leg ulcers are also a chronic and severe complication of **sickle cell disease (SCD)**. In a prospective, observational cohort study it was demonstrated that healing of SCD ulcers was independently associated with wound area and duration, rather than with SCD biological or clinical characteristics.²⁶⁹

11. Histology of atypical wounds

To provide optimal treatment it is essential to follow a diagnostic synthesis process to reach the correct assessment. In order to do this diagnostic techniques aiming at a specific diagnosis should be employed. Histological diagnosis plays an important role in the armament of these diagnostic techniques. However, while not every chronic wound has to be biopsied, a biopsy should be considered if the appearance of the ulcer is atypical or if there is deterioration or failure to progress after 12 weeks of active treatment.²⁷⁰

Biopsy technique

‘A biopsy should be considered in every chronic ulcer which has an atypical appearance, or fails to respond to adequate topical therapy after four to 12 weeks.’

Choosing the site for biopsy is an essential decision. The biopsy should be taken from the

wound edge, since histology from the wound bed will mostly show reparative and secondary findings and will not provide any useful information as to the aetiology of the wound.^{198,271} The biopsy should include epidermis, dermis and sufficient subcutaneous tissue (Fig 38). It is difficult to obtain this by the punch technique, which produces relatively superficial specimens so a narrow spindle scalpel biopsy is the preferred technique. This method also has the advantage that the defect edges can be designed and sewn under less pressure for a better healing result. A specimen yielded by a scalpel biopsy provides sufficient material for an adequate histologic examination and can be used for additional investigations (eg direct immunofluorescence if vasculitis or autoimmune bullous disease is being suspected or microbiological tissue cultures in the cases of infection). In many cases, it is also useful to consult dermato-pathologist for the right biopsy site.

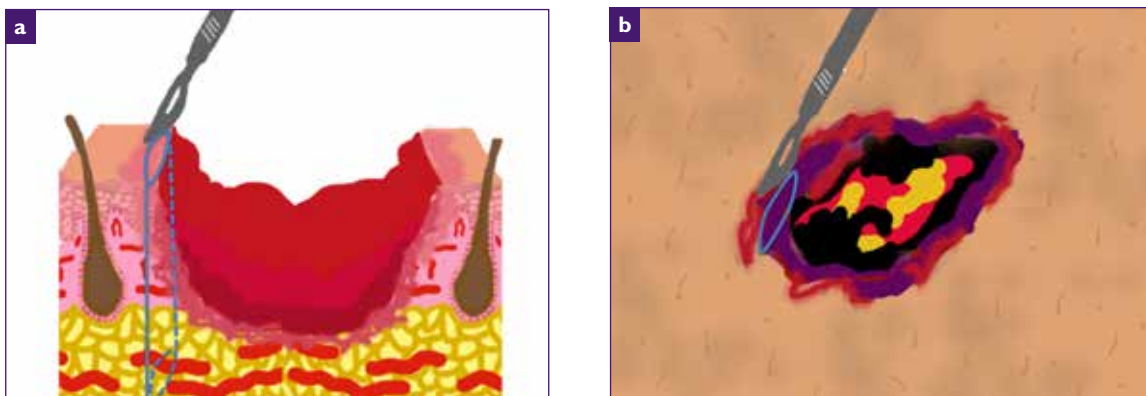


Fig 38. Biopsy technique, general basis (a). Biopsy technique, specific for purpuric/necrotic lesions (b) Drawings by Elena Conde Montero

Each specimen for routine histology should be placed into separate bottles of 10% formalin solution, while specimens for direct immunofluorescence or microbiology should be placed in saline solution if the specimen can reach the lab within 24 hours or otherwise in a special transport medium. Specific attention to labelling with the name of the patient, date, and the site of each specimen is essential. The pathology requisition form should contain a brief and relevant clinical history along with a description of the wound or lesion. Most specimens are processed for haematoxylineosin staining to examine the morphology and cellular detail of the specimen. For some differential diagnoses, the pathologist will order additional special stains. In the following the histological findings in different types of atypical wounds are discussed.^{272,273}

Vasculitis

Vasculitis is defined as inflammation directed at vessels, which compromises or destroys the vessel wall leading to haemorrhagic and/or ischaemic events.⁴³ A skin biopsy is the gold standard for the diagnosis of cutaneous vasculitis. For the highest yield, biopsy specimens for haematoxylineosin staining should be taken from an established purpuric lesion (eg <72 hours old). For direct immunofluorescence biopsy specimens, an acute lesion (<24 hours old) provides the highest yield.²⁷⁴

Secondary vasculitis due to connective tissue disorder (CTD) occurs frequently in systemic lupus erythematosus (SLE), rheumatoid arthritis (RA) and Sjögren's syndrome and less commonly in dermatomyositis, scleroderma and polyarthritides. In general, CTD vasculitis shows more widespread organ involvement. A skin biopsy is likely to show a mixed, mostly small and, less commonly, muscular vessel neutrophilic vasculitis with lesions that can resemble either typical CLA or polyarteritis nodosa (PAN); the coexistence of small and muscular vessel vasculitis in the same biopsy specimen or different

lesional skin is a characteristic feature of CTD vasculitis. Extravascular histologies can provide a clue to diagnosis of CTD vasculitis, such as the presence of interface dermatitis (eg SLE and dermatomyositis), dermal or subcutaneous sclerosis in scleroderma.²⁷⁵

Livedoid vasculopathy

Livedoid vasculopathy ulcers occur typically bilaterally in the malleolar region and are very painful. In early and ulcerative lesions an increased number of dermal vessels with intraluminal fibrin-plugs and fibrinoid vessel wall necrosis are present (Fig 39). There is usually a mild inflammatory infiltrate but no sign of destruction of the vessel walls, so that this condition should be considered as a pseudo-vasculitis or a vasculopathy. A typical sign is also porcelain white areas known as 'atrophie blanche' and signifies that the epidermis is atrophic and the dermis shows a scleroderma like hyalinisation.²⁷⁶

Cutaneous polyarteritis nodosa (CPAN)

CPAN should be suspected in patients presenting with tender nodules, livedo vasculopathy, livedo racemosa, ulcers, acral gangrene and/or neuropathy. A deep incisional biopsy, down to the fascia, is likely to demonstrate neutrophilic muscular vessel vasculitis at arterial branch points, located either at the dermal-subcutis junction or within the subcutis. Recently, two entities have been described that show clinical features of CPAN, but a lymphocytic arteritis on biopsy: macular arteritis and lymphocytic thrombophilic arteritis. These variants of vasculitis may simply represent latent or late evolutionary stages of CPAN.²⁷⁵

Pyoderma gangrenosum

PG ulcers have very variable clinical presentations, but typically show pain out of proportion and

violaceous undermined borders. Even if the histopathologic findings in PG are not specific, a biopsy is indicated in almost all instances because it is useful in the exclusion of other diseases, such as infections and malignancy. Microscopic features include massive neutrophilic infiltration, haemorrhage and necrosis of the overlying epidermis. Histologically, this finding may simulate an abscess or cellulitis. Neutrophils are often around and within the vessel walls, but the full picture of vasculitis is generally absent. The neutrophilic necrosis in the dermis is wider than the epidermal defect thus producing the aspect of undermining necrosis (Fig 40). In later chronic stages reparative changes as fibrosis can superimpose and distort the histological picture so that a negative histology does not exclude the diagnosis.²³

Leukocytoclastic vasculitis (LCV)

Although palpable purpura is the clinical hallmark of LCV, crusted ulcers as well as urticarial, bullous, nodular and pustular lesions may also be encountered. Usually the postcapillary venule and the capillary loops within the upper dermis are primarily affected, in severe cases muscular and deeper vessels may also be involved. The diagnosis of LCV is based on the finding of fibrinoid necrosis of the walls of the involved vessels associated with endothelial cell swelling, infiltration of the blood vessel walls by neutrophils and conspicuous nuclear dust and erythrocyte extravasation. Ulceration is usually associated with the finding of intravascular thrombi and overlying ischaemic necrosis of epidermis and dermis. A variable number of eosinophils and mononuclear cells are also found in the infiltrate. A high number of eosinophils may be suggestive of drug induced LCV. In later development stages an interstitial hypercellularity ('busy dermis') and histiocytes filled with cellular debris dominate the picture. It is essential to biopsy early lesions (less than 48 hours old) to find the diagnostic changes and be able to make a specific diagnosis.²⁷⁵

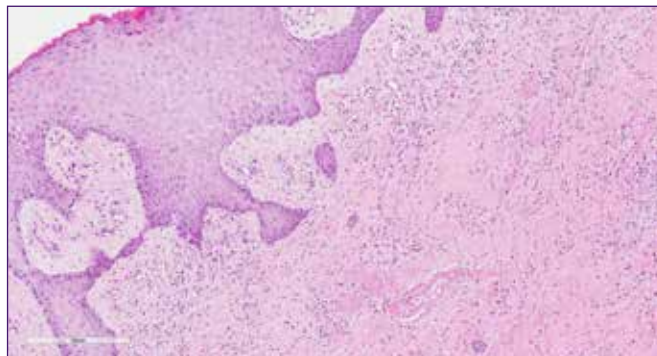


Fig 39. Livedoid Vasculopathy, HE. Dermal vessels with intraluminal fibrin-plugs and fibrinoid vessel wall necrosis is present. There is a mild inflammatory infiltrate but no sign of inflammatory destruction of the vessel walls. Picture by Jivko Kamarachev.

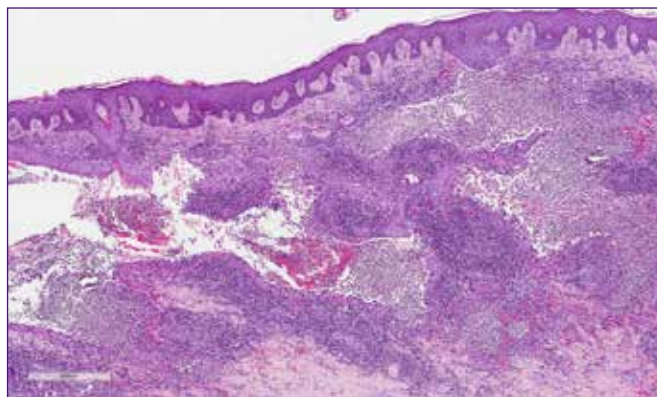


Fig 40. Pyoderma gangrenosum, HE. The neutrophilic necrosis in the dermis is wider than the epidermal defect thus producing the aspect of undermining necrosis. Picture by Jivko Kamarachev.

Cryoglobulinemia

Cryoglobulins are cold precipitable immunoglobulins from serum. Cryoglobulinemia remains asymptomatic in most cases but can lead to vascular occlusion or immune complex tissue deposition, causing cryoglobulinemic vasculitis. Monoclonal cryoglobulinemia (Type I) accounts for some 25% of cases of cryoglobulinemia and is associated with multiple myeloma, Waldenström's macroglobulinemia and chronic lymphatic leukaemia. Principal clinical manifestations are ulcerations of the lower extremities, acrocyanosis and generalised livedo reticularis. Histologically,

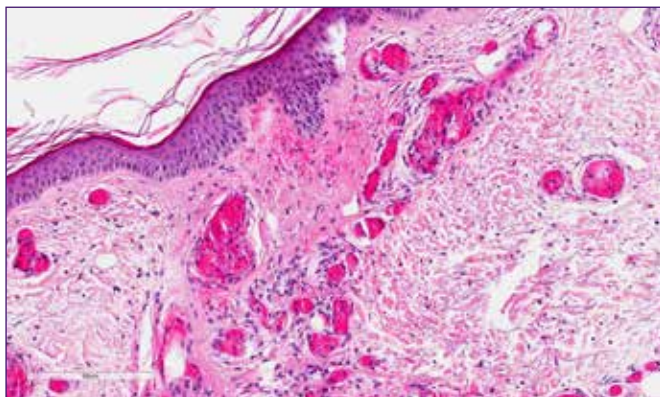


Fig 41. Cryoglobulinemia, HE: Small vessels in the upper dermis are filled with homogeneous, eosinophilic material. Picture by Jivko Kamarachev

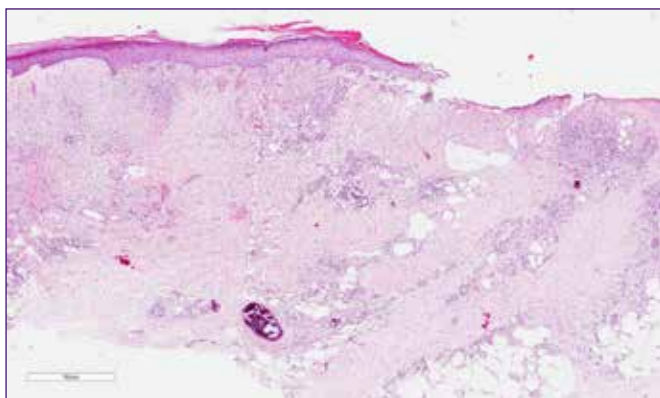


Fig 42. Martorell HYTILU, HE. Focal obliterating subcutaneous arteriolosclerosis with medial hypertrophy and calcinosis. Picture by Jivko Kamarachev

small vessels in the upper dermis are filled with homogeneous, eosinophilic, periodic acid-Schiff staining (PAS) positive material beneath the ulcerations and there is no vasculitis (Fig 41). In polyclonal and mixed cryoglobulinemias, which are most often associated with a hepatitis C virus infection, the clinical and histological picture of an acute leukocytoclastic vasculitis develops.²⁷⁷

Martorell HYTILU

Diagnostic Martorell HYTILU, is an obliterating subcutaneous arteriolosclerosis with medial hypertrophy and medial calcinosis (Fig 42). Since

these changes have a focal character as in PAN it is essential to have a sufficiently large and deep biopsy and to perform multiple serial cuts. Best results are obtained with a 5mm narrow but 3–4cm long and sufficiently deep excisional biopsy, which should be embedded longitudinally to provide a large surface for inspection microscopically.²⁷⁸

Cholesterol embolism

Cholesterol emboli originate from atherosclerotic plaques and can be dislodged in the course of endovascular procedures or anticoagulation. Predominantly the lower limbs are involved and skin lesions include purpura, livedo reticularis, ulcers and gangrene. Microscopically, clefts indicating the sites of cholesterol depositions are found in arterioles and small arteries in the dermis and subcutis. Fibrin thrombi often surround the cholesterol crystals. There may be extensive surrounding necrosis of epidermal and dermal structures. Due to the focal character of the embolic event, several and serial cuts are necessary to make the diagnosis.⁷³

Calciphylaxis

Calciphylaxis is a life-threatening condition affecting predominantly patients with chronic renal failure on dialysis with abnormal calcium/phosphorous metabolism and a secondary or tertiary hyperparathyroidism. Clinically erythematous indurated plaques predominantly on the lower limbs with a tendency to ulcerate are found. These ulcers heal poorly and are very painful. The histological hallmark is the calcification of small to medium-sized arteries and arterioles in the dermis and subcutis. In pronounced cases, diffuse interstitial calcification may be seen. Haemorrhage and necrosis may result²⁷⁹.

Necrobiosis lipoidica

Necrobiosis lipoidica (NL) affects 0.3%–1.2% of

diabetic patients.²⁸⁰ NL is characterised by single or multiple asymptomatic red to yellow shiny plaques that gradually enlarge and within which, due to atrophy, dermal blood vessels are seen on the surface. Ulceration occurs in about 15% patients with NL usually following minor trauma.²⁸¹

The histopathological changes in NL involve the whole dermis. Areas of necrobiosis are usually more extensive and less well defined than in granuloma annulare. Between the necrobiotic areas granulomatous inflammatory infiltrates is present consisting of histiocytes, lymphocytes and variable numbers of multinucleate Langerhans or foreign body giant cells. In old atrophic lesions and in the centre of plaques, there is little necrobiosis and much dermal fibrosis. The lack of pronounced depositions of mucin as detected by the Alcian blue stain helps to differentiate NL from granuloma annulare. Vascular changes ranging from endothelial swelling through wall thickening and fibrosis to overt lymphocytic vasculitis are more prominent in NL than in granuloma annulare.²⁸²

Infectious diseases

A variety of infections can cause chronic leg ulcers including: EG, tropical ulcer, atypical mycobacteria, leprosy (neuropathic ulceration), cutaneous tuberculosis, deep fungal infection and leishmaniasis.

Essential for the diagnosing of infectious ulcers are bacterial and mycological swabs and cultures. Histology is often useful providing hints of infectious origin or even a specific diagnosis if the infectious agent can be identified with a specific stain as is the case the PAS-stain identifying fungi, Gram-staining for bacteria, Giemsa-Stain identifying *Leishmania* and Ziehl-Nielsen stain which may be useful to identify mycobacteria. Histological findings suggesting an infectious ulcer include hyperplasia of the epidermis which may reach pseudo-epitheliomatous

dimensions, a mixed inflammatory infiltrate with foci of dense neutrophilic granulocytes and formation of granulomas with or without caseation and admixtures of numerous lymphocytes, plasma cells and some eosinophils.

EG is typically associated with *Pseudomonas aeruginosa* septicaemia but similar lesions have been observed in patients with other bacterial, fungal and viral infections. The lesions of EG result from bacterial invasion of the walls of arteries and veins in the skin and subcutaneous tissue. Impaired immunity through the known predisposing factors leads to increased susceptibility to infections.

Histopathology of EG lesions shows vascular necrosis and intravascular thrombosis with a scarce mixed inflammatory infiltrate and with basophilic deposits suggestive of bacterial colonies surrounding the affected vessels. In sections stained with Gram stain, Gram-negative rods are identified. Blisters, haemorrhage, oedema and necrosis are seen in the surrounding dermis. However the histological findings are highly variable dependent upon the evolutionary stage of the lesion, which may be affected by temporal and therapeutic factors. Correlation with the clinical picture, and the results of the tissue culture, and blood culture is essential.

Tumours

SCC can arise *de novo* on the lower leg or as a complication of chronic leg ulcers. SCC arising within a leg ulcer has a far worse prognosis than actinically induced SCC arising *de novo* on the lower leg. This is often compounded by a delay in diagnosis.²⁸³ Chronic ulcers that are unresponsive to treatment, with new ulcer extensions or new growths within or at the ulcer margins, should be carefully examined for signs of SCC and biopsied if indicated. If a poorly or moderately differentiated SCC is found, early and aggressive surgical intervention is essential.

BCCs are also found as ulcerating forms on the lower leg. Histology is typical presenting a basophilic epithelial tumour connected to the epidermis, consistent of tumour cell strands and complexes with a palisading arrangement of the tumour cells in the periphery and with a well-developed fibrous stroma with typical retraction artefacts between tumour and stroma.

The lower legs are a predilection site for Kaposi sarcoma in which an atypical vascular proliferation is found in the reticular dermis, with prominent erythrocyte extravasation and numerous plasma cells in the tumour stroma. Immunohistochemistry demonstrating human herpes virus 8 (HHV8) in the atypical endothelia supports strongly the diagnosis of Kaposi sarcoma.

The lower leg is also a predilection site for the high grade diffuse large B cell lymphoma of the lower leg, an aggressive entity which may present as a quickly growing ulcerated tumour with an aggressive course and fatal outcome. Histology showed dense sheets of large CD20+, bcl2+, MUM1+ B-cell blasts in the dermis and subcutis.²⁸⁴ Even melanoma of the acral lentiginous type can be disguised as a DFU and only histology can provide an adequate diagnosis.²⁸⁵

Drugs

Although anecdotic case reports of ulcers arising in association with the intake of a plethora of medications exist in the literature the best documented associations in large series concern hydroxyurea and coumarin.

In one study of 41 cases of leg wounds due to therapy with hydroxyurea, biopsy specimens were taken from 11 patients. Histopathologic findings

showed epidermal atrophy, dermal fibrosis, and scar tissue without vascular lesion. In one case a few small capillaries were occluded, as in livedoid vasculitis, but direct immunofluorescence staining findings were negative. In another case there were fibrinoid deposits in the dermis with extravasation of red blood cells and leuko-cytoclastic vasculitis.²⁸⁶

In coumarin necrosis, sections show variable degrees of epidermal and dermal necrosis. There are extensive intravascular thrombi within capillaries and venules. There remaining patent vessels are dilated.^{88,287}

Others

Acute exogenous noxious substances (physical, chemical, including as a manifestation of auto-aggression) can lead to acute toxic changes in the skin which may have typical histological presentation — pale necrosis of the epidermis and sometimes of the dermis with only scarce neutrophil granulocytes infiltrate in the surrounding viable tissue and no signs of vascular damage or inflammatory process which could account for the necrosis.

Conclusions and recommendations

Histology is an important diagnostic tool in atypical wounds. A chronic wound should be biopsied if atypical in appearance or failing to respond to adequate therapy after a maximum of 12 weeks. The biopsy should be taken from the wound edge. A deep narrow but sufficiently long and deep spindle biopsy comprising epidermis, dermis and subcutaneous fat provides optimal material for histological diagnosis. Providing the pathologist with a concise clinical history and description increases the chances of obtaining a specific diagnosis.

12. Practical aspects of diagnosing and treating atypical wounds

Successful wound management relies heavily on the rapid and precise diagnosis of the aetiology of the wound.⁸ Even evidence-based wound management is destined to fail without the exact diagnosis. The most common chronic wound aetiologies are venous, arterial, mixed venous and arterial leg ulcers, DFUs and PUs.^{6,288} If the wound does not fit within these typical presentations, an atypical cause of wound should be suspected.^{6,7} Prompt and exact diagnosis is essential also as many of the atypical wounds need specific treatment differing from the traditional ones and an incorrect diagnosis can lead to devastating outcomes and increased mortality.^{10,11,100}

Diagnosis

For diagnosing atypical wounds it is very important to take a thorough patient history including a neurovascular assessment, which can help to provide important information in order to reach a diagnosis (Table 11).

The appearance of the wound and the surrounding skin is also important. Hypergranulation, pathergy, violaceous and undermined borders, necrosis, atypical location, severe pain (out of proportion which is normally associated with wounds), livedo racemosa and reticularis and rapidly progressive ulceration are signs of an atypical cause

(Fig 46).^{6,7,234} Wound assessment is a continuous process, therefore it is important to establish whether the wound is decreasing in size with signs of healing by proper treatment (compression therapy, offloading, optimal local therapy).

If a wound is initially classified as venous or neuropathic but subsequently does not show signs

Table 11. Patient history related to the risk of atypical wound occurrence

Inflammatory bowel disease, rheumatoid arthritis, hematologic malignancy?	PG?
Uremic disease, dialysis?	Calciphylaxis?
Hypertension, obesity, type II diabetes?	Martorell HYTILU? Hidradenitis suppurativa (HS)
Rheumatoid arthritis, connective tissue disease?	Vasculitides?
Vitamin K antagonist medication?	Calciphylaxis, Martorell HYTILU, Coumarin necrosis?
Hydroxyurea medication?	Hydroxyurea-induced ulcers?
Travel history, refugee?	Leishmaniasis? Tuberculosis?
Older age, immunosuppression, long persistence?	Malignancy?
Personality disorder?	Artefactual ulcers?
Recurrent lesions in the axillae, under the female breast, ano-genital region or groin?	HS?

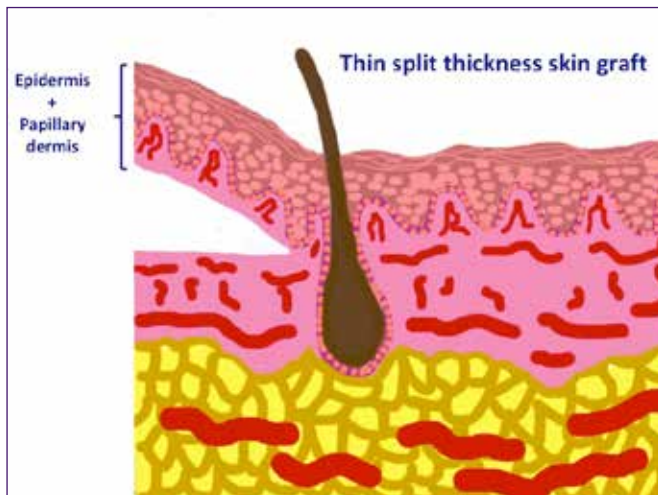


Fig 43. Thin split-thickness skin graft. Drawing by Elena Conde Montero

of healing during 4–12 weeks, at least one biopsy should be taken (see Ch. 11 Histology of atypical wounds).⁹ In case of suspected infectious ulcers, a wide biopsy for tissue cultures for atypical bacterial, mycobacterial and fungal infections should be taken.⁶

In order to obtain a reliable specimen, the biopsy should be taken with a scalpel from the wound edge. When suspecting Martorell HYTILU and ulcers associated with calciphylaxis punch biopsies do not usually obtain a specimen deep enough therefore a wide biopsy is preferable (see Ch.5 Martorell HYTILU and calciphylaxis). Punch biopsies can be used if malignancy is suspected, but in case of diagnosing other atypical wound aetiologies, they usually do not obtain a specimen deep enough. In case of vasculitides, in addition to the biopsy specimen, a specimen for direct immuno fluorescence (DIF) should be taken. For this, an acute lesion (<24 hours old) provides the highest yield.^{274,289} Preferably the histopathological and DIF specimens should be analysed by a dermatopathologist who is experienced in atypical wounds. However, it is important to remember that a negative histology does not exclude an atypical wound; also a

clinical assessment is needed and the patient should be referred to a dermatologist.⁷

In addition to an atypical wound on the leg, patients may also have concurrent arterial and/or venous insufficiency. Therefore, careful arterial evaluation (pulse palpation, measurement of the ankle-brachial pressure index (ABPI)) is needed for every patient. If the patient has signs of venous insufficiency, a duplex ultrasound of lower extremities should be performed. Exclusion of neuropathy using microfilament sensory testing is also crucial. In addition to these tests and the biopsy specimen, measurement of blood pressure and further laboratory testing is often needed. This includes complete blood cell count, metabolic profile, urinalysis and possible stool guaiac test. If vasculitis or vasculopathy are considered, then testing should include also anti-nuclear antibodies (ANA), anti-neutrophilic cytoplasmic antibodies (ANCA), rheumatoid factor, anticyclic citrullinated peptide, serum protein electrophoresis, hepatitis profile, cryoglobulins, lupus anticoagulant, antiphospholipid and anticardiolipin antibodies, protein C, protein S, factor V Leiden and antithrombin III levels, cryofibrinogens and coagulation.^{6,290}

Treatment

Once a diagnosis has been established an interdisciplinary approach should be adopted in order to reach a successful outcome. This might include one or more of the following health professionals (eg dermatologist, vascular and plastic surgeon, nephrologist, rheumatologist, tissue viability nurse, podiatrist).²⁸⁸ The exact nature of the treatment relies on the specific type of an atypical wound and will be presented in the individual chapters of this document. Where patients with a wound are being treated by immunosuppressive agents, NPWT and skin grafting can also be considered but only after the inflammation has been reduced by immunosuppressive therapy (Fig 43).²⁹¹

The use of local corticosteroids in PG is widely accepted. However, topical corticosteroids may also help to reduce excessive inflammation that impairs wound healing in other atypical wounds.^{7,288,292} Local application of corticosteroids to the wound bed are well known to reduce hypergranulation. However, they have also other benefits, such as limiting the spread of necrosis in Martorell HYTILU and other necrotising vasculitides²⁹³ (see Ch. 13 Topical treatment for atypical wounds).

As the immunosuppressive agents can cause delayed wound healing, advanced therapies,²⁹⁴ epidermal grafting²⁹⁵ and surgical procedures are important also in terms of reducing healing time. It is also possible to perform punch grafting, which is a traditional method to obtain thin split-thickness skin grafts containing epidermis and papillary dermis (Fig 44).

Grafts are obtained under a local anaesthetic with a punch, curette or surgical blade and are placed directly on the wound bed. The donor site is normally the thigh, which subsequently heals by secondary intention. This procedure can be performed in an outpatient basis^{144,296,297} with 100% graft uptake (Fig 45). However, there may be occasions where grafts do not adhere but it is still useful as they release growth factors, cells that promote wound epithelialization and reduce pain.^{144,296,297} Local pressure and immobilisation during the first 3–4 days after the procedure is essential for graft taking.

The first dressing change should take place 5–7 days after the surgical procedure. During subsequent dressing changes it is essential to avoid excessive cleansing in order to avoid altering the healing environment.¹⁴⁴

Compression therapy (as provided by bandages, hosiery or compression wraps) can be beneficial for the majority of leg ulcers with oedema, even if the cause of the wound is not venous. After

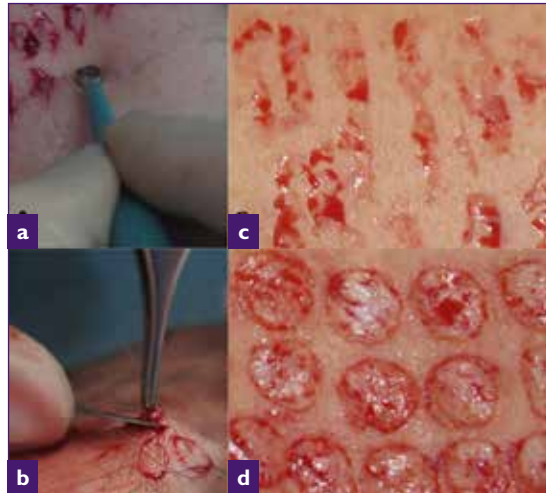

Fig 44. Grafts obtained with a curette (a). Grafts obtained with a punch and surgical blade (b). Point-like bleeding is observed after graft excision (c and d). Pictures by Elena Conde Montero

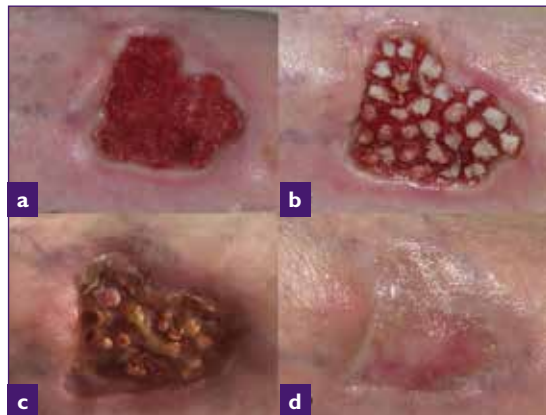


Fig 45. Chronic ulcer secondary to vasculitis (a). Grafts obtained with surgical blade placed on the wound (b). Clinical aspect 3 weeks later (c) Complete epithelialisation seven weeks after the procedure (d). Pictures by Elena Conde Montero

exclusion of advanced peripheral arterial occlusive insufficiency arterial, compression therapy should be used in all patients with lower leg ulcers.²⁹⁸ However, compression therapy may be painful in patients with inflammatory PG or vasculitides, therefore lower pressures of 20mmHg should be used initially⁴¹ (see Ch. 2 Pyoderma gangrenosum).

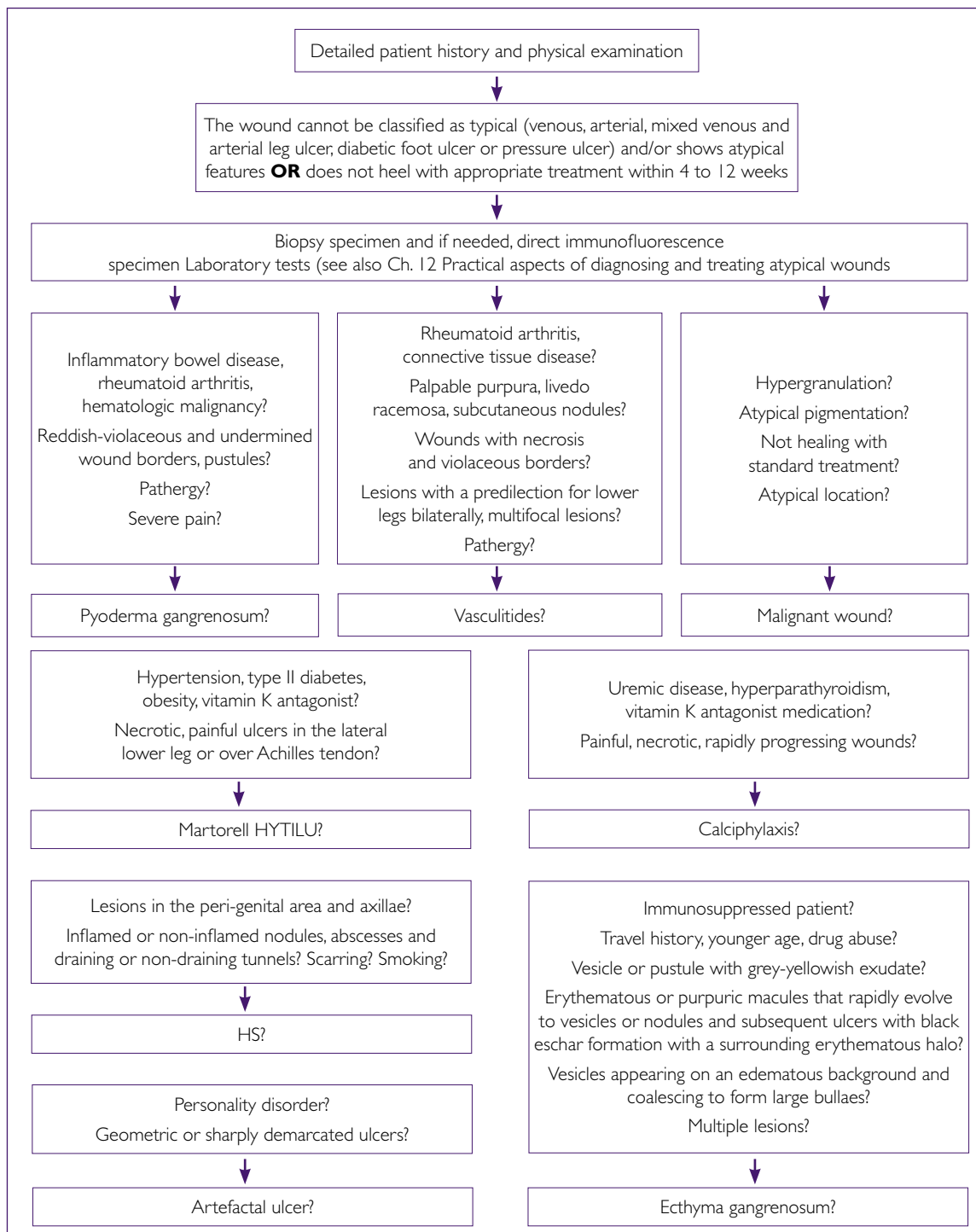


Fig 46. Algorithm for diagnosing atypical wounds

The local therapy of atypical wounds is described in detail in the chapter 'Local treatment of atypical wounds'. In the first phase of treatment, it is generally recommended to use gentle, non-adherent dressings to avoid the pathergy phenomenon.

Conclusion

In cases where the wound does not fit into the typical aetiologies, it is important to stop and think whether an atypical wound is possible (Fig 46). The best approach is to consult an expert in atypical wounds, such as a dermatologist. The treatment relies on an interdisciplinary approach.

13. Topical treatment for atypical wounds

When treating atypical wounds, it is necessary to ensure a holistic assessment and appropriate clinical examination of the patient to ensure an accurate diagnosis can be made before any treatment regime is initiated. Determining the aetiology of the wound can be challenging as many of them mimic other wounds so further investigations including a biopsy sample may be needed.²⁹⁹

Assessment

The patient, the wound and the environment must be assessed to ensure a successful outcome. The patient needs support in their environment to ensure dressing changes are done in a timely way either in the community or the clinic using an aseptic technique to prevent further infections or trauma. The patient's lifestyle needs to be addressed including diet, smoking cessation and exercise to promote wound healing. Assessment of the patient's perfusion, pain levels and factors that influence healing including comorbidities need to be incorporated in to the plan of care before any dressing choice is made.³⁰⁰ The wound assessment itself includes size, depth, tissue, exudate, odour, and periwound skin. If infection is suspected a wound specimen is needed for culture and sensitivity to ensure appropriate antibiotics are used. Equipment such as pressure redistribution devices aim to reduce shearing forces and address the microclimate to preserve skin.³⁰¹ A collaborative approach between patients, relatives, carers, health professionals, industry and the organisation will ensure high-quality care delivery for patients.

Preparation is needed to establish a plan of care. Availability of resources may vary from country to country. Listening to the patients' needs with empathy will increase adherence and gain trust. The 'goal of the week' or treatment rationale should be agreed by the team and initiated with the appropriate treatment and dressing regime. Weekly assessment and measurements of the wound need to be recorded and if no improvement is seen after four weeks a specialist referral is required.³⁰²

Cleansing

Cleansing wounds has been debated in the literature and currently there is a dearth of literature available on which solution is best for reducing infection and promoting wound healing.³⁰³ However, Hodgkinson & Nay suggest it is essential for effective skin care to remove dry scales, assess the leg fully and most importantly it makes patients feel better.³⁰⁴ The British Association of Dermatology (BAD) guidelines 2014 recommend that patients 'Should be encouraged to wash their legs in warm potable tap water when bandages are changed'.³⁰⁵ Legs should be washed using a soap substitute for example hydromol.³⁰⁵ The limb should be thoroughly dried paying attention to the skin between the toes.³⁰⁶ Dried exudate and devitalised skin adhering to the wound and surrounding skin will only promote the production of bacteria so removing it using a good skin care regime is recommended. Solutions such as hydrogen peroxide, iodine, potassium permanganate, chlorhexidine, saline and water are used for cleansing and topical treatments of atypical wounds to reduce bacterial bioburden

and biofilm in wounds, but more robust research is required to definitively assist clinicians in their choice of cleansing agent.³⁰⁷ Recognising signs of infection and managing it is imperative for patients with atypical wounds.³⁰⁸ Lastly, using an appropriate emollient afterwards will prevent cracks in skin and dry scales building up.³⁰⁹

Topical steroids

Chronic wounds, particularly atypical wounds, are commonly characterised by an excessive inflammatory response, with a greater number of inflammatory cells such as neutrophils, lymphocytes and macrophages.³¹⁰ This results in the wound getting stuck in a chronic inflammatory phase with high levels of cytokines, MMPs and reactive oxygen species. This results in excessive degradation of the ECM and progression of wound healing.³¹¹ Therefore, the use of topical steroids may be useful in treating these wounds. A study by Taheri et al. suggests that topical corticosteroids can be used to suppress inflammation and fibroblast activation in the treatment of burns to reduce the incidence of hypertrophic scarring and keloids.³¹² Also, case series exist of the successful use of topical steroids in the treatment of excessive hypergranulation.³¹³ However, they are not commonly used in general wound care practice.

Topical steroids can be used as a single steroid topical agent or in combination with antimicrobial and antifungal agents in wounds displaying excessive and abnormal inflammatory features despite good clinical wound care practice.²⁹²

Topical steroids should be prescribed by health professionals with prescriptive authority only and used in compliance with local policy and medicinal regulatory body. A combined topical agent is often first choice as single steroid agents typically increase the risk of infection and thin the lining of skin.³¹⁴ A study of chronic wounds including atypical wounds such as (vasculitis, PG, mixed vessel disease ulcers, rheumatoid ulcers) demonstrated that using a combined topical steroid, antifungal and antibiotic improved healing rates and reduced exudate and pain symptoms for patients.²⁹² The study recommends that topical steroid treatment should be considered when abnormal inflammation is present in chronic wounds but only when the correct diagnosis is made and where the patient can be monitored carefully.

Dressings

The health professional carrying out the dressing must be trained skilled and competent. Using a framework such as 'TIME' can aid the selection of appropriate dressings.³¹⁵

T=Tissue: good tissue perfusion is essential for wound healing. The presence of necrosis or devitalised tissue hinders this and therefore needs to be removed by an appropriate method. Some atypical wounds may need regular debridement. However, some atypical wounds cannot be debrided for example active debridement can be deleterious in the active inflammatory phase of vasculitic ulcers and pyoderma gangrenosum. But when the immunosuppressive treatment has reduced the

inflammation, then topical treatment to debride the wound can be carried out. A full overview of approaches to debridement can be found in the *'EWMA Document: debridement: an updated overview and clarification of the principle role of debridement.'*³⁸

I=Infection: establishing the cause of infection is necessary to ensure appropriate use of antimicrobials. In atypical wounds, the presence of bacteria delay healing therefore reducing the wound bioburden should reduce adverse effects. In cases of infections, antibiotics may be indicated, but holistic assessment of the patient is needed first to ensure correct diagnosis is made. Many patients with PG have completed multiple courses of antibiotics before being diagnosed. The use of antiseptics may prevent the development of infections that will minimise antibiotic use, as well as promoting quicker healing. The use of topical antimicrobial therapy may be especially helpful for example, the eradication of bacteria before grafting for patients with atypical wounds.^{307,316} A full overview about the EWMA position regarding antimicrobials and non-healing wounds can be found in the *'EWMA document: Antimicrobials and non-healing wounds. Evidence, controversies and suggestions'*³¹⁷ as well as by following the EWMA Antimicrobial Stewardship campaign which is being developed in partnership with the British Society for Antimicrobial Chemotherapy (BSAC).³¹⁷

M=Moisture: exudate facilitates the inflammatory response and aids autolytic debridement and epithelisation. Wound exudate should be assessed at dressing change noting colour, amount, high viscosity, odour and consistency. However, too much moisture can lead to maceration and damage surrounding skin.³¹⁸

E=Epithelial cells: will migrate across the wound by active cell division. The wound edge needs to be healthy for wound closure to occur.

Dressing selection should be based on the condition of the wound bed and the nature/tissue types present. Key considerations should include:

- Promote a moist wound healing environment
- Management of tissue types present, necrosis, slough, granulation
- Management of exudate
- Management of infection
- Promote haemostasis if bleeding present
- Management of odour
- Protection of the periwound environment
- Atraumatic dressing change
- Comfortable and aesthetically acceptable to patients.

Pain

Pain is a common feature of atypical wounds. Therefore, a validated assessment tool should be used to establish an individual's level of pain and ensure analgesia is given before dressing change as many patients with atypical wounds suffer unnecessarily before, during and after dressing changes if pain is not managed well.

Avoiding adhesive dressings such as gauze to minimise pain or trauma to surrounding tissues is essential.³¹⁹ Consider the wear time, moisture balance levels to ensure comfort for patients.

Wounds as associated with calciphylaxis and PG can be particularly painful. Non-adherent, sensitive dressings have been found to be practical in clinical use, as PG and vasculitis wounds have the pathergy phenomenon, ie they worsen with minor trauma.

The use of an easy to apply multifunctional dressing such as polymeric membrane dressings capable of stimulating the healing process, providing pain relief and continuous wound bed cleansing, can simplify dressing selection and involve patients in their care.³²⁰

Dressings

There are many dressings available but agreeing a 'goal of the week' can help to aid in the selection for clinicians. If an allergy to the dressing is suspected or if evidence of contact dermatitis patch testing is required as soon as possible.

Categories of dressings include:

- Passive simple dressings used for protection such as surgical pads useful for absorbing minimal exudate
- Active dressings, which interact with the wound bed, such as for example polymeric membrane dressings are useful in gently softening and debriding hard eschar in wounds associated with calciphylaxis
- Advanced therapies interact and advance wound healing such as larvae therapy for example are useful in managing complex challenging wounds.

Dressing types include the following:

- Alginates
- Antimicrobials
- Foams
- Transparent Films
- Hydrocolloids
- Gelling fibre
- Hydrogels
- Hydropolymers
- Non-adherents
- NPWT
- Polymeric membrane dressings
- Super absorbers.

NB: Please refer to your local dressing formulary regarding sizes, cost, indications etc. Specifically regarding NPWT please refer to the 'EWMA Document: Negative Pressure Wound Therapy'.³²¹

14. The patient perspective

The negative impact of wounds is well recognised in the literature with many patients suffering with anxiety and depression. Many patients with atypical wounds suffer daily both physically with odour, exudate, pain, reduced mobility and psychologically with negative emotions, loneliness and depression.¹⁴ Mortality rates are higher for patients with atypical wounds not only due to their comorbidities and lower socio-economic circumstances leading to higher rates of suicide but for many there can be a delay in diagnosis prolonging their pain and suffering.³²² Stress has also been shown to impact negatively on wounds by reducing healing rates.¹⁵ There is a dearth of literature written about the impact of atypical wounds, despite these wounds being a chronic condition. Therefore, a literature review of the patient perspective of chronic and atypical wounds was included in the search.

Autonomy

Understanding wound care from a patient's perspective is the hallmark of a successful practitioner.³²³ Sleep deprivation, pain or loss of independence can make the patient appear to be difficult to clinicians. But the reality is when they suffer in this way in addition to wound pain they often feel they are not listened to. Loss of autonomy means a lack of control and this can be frustrating for many patients who want to have their independence. Proper symptom management can improve a patient's QoL. When they are involved in their care and an agreed plan is in

place adherence is more likely to occur leading to success of wound healing.

The incidence and prevalence of chronic wounds including atypical wounds is likely to increase. With an aging population and increases in the prevalence of obesity, diabetes and lower extremity arterial disease many patients have several comorbidities resulting in hard to heal wounds.³²⁴

Therefore, encouraging patients to be independent and engaged with their wound care is needed. Avoiding hospital admissions and managing in their homes is encouraged to improve QoL and reduce the cost to health services. Some patients need to work and cannot afford time off to attend clinics where as others, perhaps the elderly, see the clinic as an opportunity to engage with others.

Patient involvement

Patient involvement has long been recognised as a key to success in the management of chronic atypical wounds.³²⁵ Ensuring dignity and respect is essential in the delivery of high-quality care. However, this can lead to conflict when patients dispute with health professionals regarding what they want and what they get.³²⁶ Many of these patients have been treated with many products and medications before an accurate diagnosis is made.¹⁰³ Communication and understanding of these complex wounds is essential to empower patients and to ensure the correct diagnosis is obtained and patient engagement is achieved. From this perspective it is possible to identify

wellbeing as more of a priority for the patient than wound healing.

Education

Education is important for health professionals and patients. Health-care staff need to improve their knowledge base and their ability to teach. Informing the patient in a language they can understand and internalise is important for their understanding. This message needs to be delivered at an appropriate level of contextualisation of the individual to ensure their efforts in health promotion are engaged, for example smoking cessation is more effective when the smoker is engaged. Flexibility of the content, context and delivery methods will aid in the full impact of patient understanding and engagement.³²⁷ For example, some like videos and some prefer leaflets. Elderly people may not be comfortable with information technology.³²⁸

Patient expectations

It is equally important to identify the expectations of the patient when prioritising treatment. For example, patients need to understand that a biopsy is only a diagnostic and not a treatment for skin cancer.¹⁰³ Therefore, a contract or agreed plan of care should be implemented following a thorough assessment with the patient to ensure both clinicians and clients can reach mutual goals. Informed decision-making by way of appropriate information and tools allow us to gain consent in a way that allows the patient to take charge of

their situation. Reassessment and actions recorded ensure progress is being made and appropriate referrals are made in a timely fashion when required. Communication between members of the MDT is accurate when recorded and prevents replication of requests especially when all members of the team use electronic patient record.³²⁹

Patient capacity

Allowing time to express their concerns can be challenging in a busy clinic but a chance to be involved and take ownership should be offered to the patient.³³⁰ Wounds International argue, health care professionals have a duty of care to act as advocates with the patient's best interest by ensuring the patients care is a priority and where possible to involve patients in shared decision making at all stages even when wound healing is not possible.³²⁴ However, patient capacity needs to be considered when health professionals are making a clinical judgement with the patient's best interest at the forefront. Sometimes we do not always agree with the patient decision and sometimes they delay surgery when recommended but if fully mentally competent then that's their choice and we both must live with the consequences. Multidisciplinary meetings can be useful in this scenario where other health professionals can share their thoughts and experiences in dealing with these patients.

Patients are no longer passive in their care and this has been facilitated by having internet access and being empowered through national frameworks. The UK Department of Health in

2011 implemented a strategy of no decision about me without me which demonstrates value in the management of chronic care.^{331,332} Patient outcomes are measured by levels of satisfaction and their experience as well as safety of treatments. However, a study by Green et al.³³³ demonstrated that 38% of patients did not raise their concerns. Indeed 8% who did were not acknowledged or disregarded by their community nurse. If shared decision making is the future of wound care, then we need to examine our consultation skills. However, increases in qualitative research demonstrates patients want more choice over their care dressings and other treatments.³³⁴ We need to work with our patients if we are to get the best out of this resource largely ignored in the past.

Digital imaging

A study explored the patient perspective of using digital imaging to monitor the progress of their wound. This process demonstrated that patients were open to the idea and they felt it was beneficial not only for their own progress but also felt it was a positive teaching tool for health professionals. Participants felt that when used in conjunction with wound measurements and description elicited an accurate record of their wound. The study also showed that most patients did not care who took the photo a doctor, nurse or photographer nor were they concerned whether it was a hospital or personal device. However, due to introduction of General Data Protection Regulation, this has changed. Having a secure accurate measurement of the wound is essential for record management.¹⁴

Quality of life

Patients with atypical wounds need psychological support and assistance from several members of multidisciplinary team not only delivering wound care but, also in accessing and engaging in the resources needed for them to cope day-to-day in

basic needs and companionship to become valued members of society again.³²⁹ A study demonstrated that social support mechanisms helped patients to cope better with their treatment and have a better QoL.³³⁵

A phenomenological Portuguese study in 2017 involving ten patients living with chronic leg ulcers reported that they felt limited, depressed, anxious and isolated. They were embarrassed about the odour, leakage of the wound in bed with their partner and many felt they were isolated from social events. They found comfort in their religious belief which helped them to cope. Understanding the lived experience of patients with atypical wounds by using validated HR QOL tools allows us to develop solutions tailored to patient needs.^{334,336}

Conclusion

Research, case-controlled studies and audits help us to understand the patient perspective of these complex wounds and plan our resources where needed most. Data from research allows for standardisation and consistency in decision pathways. Care pathways allow patients to understand the process and to gain trust in the health professional. Reassurance is very often what they need and an understanding of the rationale for their treatment. Appropriate and timely access to care is also a key performance indicator. We have a duty to ensure the safe delivery of quality care by reducing risks such as surgical site infection (SSI) and abiding by international evidence-based guidelines. Moore et al. emphasise that a good multidisciplinary approach is paramount for good wound care management.²⁸⁸ Another article points out that patient held records gives ownership to patients allowing for continuity of care and shared care if they are responsible and can locate the notes or remember to bring them with them to clinic.³³⁷

An electronic card that patients could carry may be of benefit but not for all patients. Patient related outcome measurements (PROMS) are a good way to ascertain if patient needs are met. A pilot study demonstrated this method using an online questionnaire filled in by patients with a tablet or online computer giving valuable and reliable data on the patient experience of arthroscopy and an option to seek a follow-up appointment only when needed reducing unnecessary routine appointments.³³⁸ It is this increased level of understanding that leads to informed choice, which leads to better care with finite resources from the patient perspective, which is what we want.

Recommendations

There is still very little evidence available to health professional to deal with the complexity of what it is like to live with atypical wounds for patients. However, if we are to meet the patient's needs and work corroboratively outcomes will be better. There is an opportunity for health professional to learn from both experience and available literature to improve pathways and ensure correct diagnosis is made so that correct management is delivered. Improvements in education regarding atypical wounds is necessary for both clinicians and patients. Lastly, further robust research studies are needed to measure outcomes such as quality of life and pain management strategies not just wound healing outcomes.

15. Health economy and organisation

The cost of management of atypical wounds is largely unknown due to the varied aetiologies and because data is often incorporated in chronic wound and lower leg ulcer studies. However, both financial and human costs can be considerable in the case of atypical wounds as there is often a delay in diagnosis and patient comorbidities and chronic inflammation cause stalled wound healing. Due to the rarity there is an absence of high-quality evidence in the management; studies often include a range of low-quality evidence-based topical and systemic treatment options and studies are often problematic as recruitment is difficult. Conditions such as PG are clinically diagnosed after excluding other diagnoses, because usually there is no specific diagnostic tests or histological findings,³³⁹ so there can be a delay in the commencement of treatment, causing further financial and human cost.

A comprehensive introduction to the elements and methodologies of wound care related health economic studies is beyond the scope of this document but can be found in the 'EWMA Outcomes in controlled and comparative studies of non-healing wounds' document.³⁴⁰

Cost to the health economy

An estimated cost of atypical wounds to health economies is limited. The cost of chronic wounds in general is well documented³⁴¹ and is expected to escalate with an ageing population as well as increasing prevalence of obesity and diabetes and other autoimmune diseases, which will further

increase costs to patients and health care resources in the coming decades.

There are over 400,000 Australians living with a chronic wound.³⁴² A third of the wounds are present for at least six months and one in five for a year or more.³⁴² In Australia, AUD\$3 billion per year is spent on chronic wounds, an estimated 2% of the national health-care expenditure.³⁴² Similar results are seen in other Western countries. In the UK treatment of chronic wounds accounts for 3% of total health-care expenditure,³⁴³ and a study from Wales using National Health Service (NHS) data concluded that chronic wounds have a prevalence of 6% and consume at least 5.5% of NHS expenditure.^{342 345} Approximately 2.2 million patients have a chronic wound³⁴⁴ with the annual NHS cost of managing these wounds and associated comorbidities being £5.3 billion.³⁴¹ Across Europe, 2–4% of health-care expenditure is spent on wounds and this figure is on the rise.³⁴³ The average cost of treating a wound ranges from €6,000–€10,000 per year.³⁴³ In addition to the initial cost of a wound to healing, it is common for wounds to recur resulting in ongoing costs for many years.

Cost to organisations

Chronic wounds impose huge costs on health services and organisations. Information about cost is useful for raising the profile of the problem among decision makers and also provides estimates of the savings if the problem is reduced. Data on the treatment cost of wounds for

organisations are inconsistent and vary depending on disease process methodology and evaluation method. The lack of evidence impedes health-care decisions, policy development and improvement in resource allocation and optimisation of the cost-benefit ratio.

The STOP GAP trial, a multicentre randomised control trial was conducted to provide better evidence to guide clinicians to improve treatment decisions for patients with PG.³³⁹ As part of this study, Mason et al. compared the cost-effectiveness of cyclosporin and prednisolone as first line treatment for patients with PG as a preferred use of NHS resources.³³⁹ For patients with small lesions <20cm² neither treatment was more cost-effective than the other.³³⁹ However, cyclosporin treatment was found to be a cost effective option in patients with large lesions (>20cm²) and there was a reported improvement in QoL.³³⁹ Decisions about treatment will continue to be informed by patient preference and drug adverse reactions; however the study suggested NHS resources would be better directed to cyclosporin than prednisolone in terms of cost-effectiveness and improved QoL outcomes for patients who have large wounds and is likely to reflect routine care in this setting.³³⁹

This economic evaluation is the first published cost-effectiveness analysis relating to PG and it opens up opportunities for further research in this area.³³⁹

There is often a delay in diagnosis also for patients with HS. Health resource use, including direct

and indirect costs for treating HS is limited. This chronic, progressive, painful and debilitating skin condition affects a younger population often requiring ongoing lifelong treatment and wound dressings.

Studies have demonstrated the increase in use of emergency department and inpatient admissions for patients with HS.³⁴³ A retrospective cohort study conducted in the UK revealed the high burden of frequent outpatient, emergency and inpatient attendances, with the majority of hospital admissions under the care of surgical specialties.³⁴⁵ Using Hospital Episode Statics data from 1 April 2007 — 31st December 2013, 11,359 patients were studied. There were 65,544 inpatient admissions; 43,773 emergency attendances and 303,204 outpatient appointments.³⁴⁶ Based on the mean number of admissions per patient per year, the mean hospital resource use cost for a patient with HS was £2,027 per patient per year.³⁴⁶

As the majority of patients in the study were of working age, the socioeconomic impact of time lost from work associated with frequent hospital visits is significant and likely to be consistent with a reported loss of 2.7 work days per year.³⁴⁷ In a survey of employed patients with HS in the US, 58% reported that the disease caused work absence, with a mean absence of around 34 day's annually.³⁴⁷

Skin cancers associated with non-healing wounds of the lower leg may result from malignant transformation as seen in a Marjolin ulcer or may arise and mimic a leg ulcer and be treated as

vascular in origin, delaying the correct diagnosis and appropriate treatment.¹⁷⁸ The two main forms of skin cancers are SCC and BCC, the latter being the most common. These NMSCs are the most common cause of cancer and one of the few malignancies of increasing incidence especially in Caucasian populations.³⁴⁸ The incidence of melanomas is also increasing and together with the rarer Merkel cell carcinoma, both tumours are aggressive depending on the stage of diagnosis and costly to treat with options such as surgery, chemotherapy, immunotherapy, radiotherapy and ongoing monitoring for recurrence.

In Australia, general practitioners see over one million patient consultations per year for skin cancers and the cost to the economy in medication, clinical and procedural treatments, pathology and diagnostic tests is the highest cost to the health system of all cancers.³⁴⁹ The majority of skin cancers are caused by exposure to the sun and the incidence is one of the highest in the world, two to three times the rate in Canada, the US and the UK.³⁴⁹ In 2010 it was calculated that the total cost of NMSC (diagnosis, treatment and pathology) was \$AUD 511 million and was estimated to increase to over \$700 million in the coming years.³⁴⁹

Clinical practice guidelines are increasing in the field of wound care and dermatology, but gaps exist in demonstrating their cost-effectiveness for organisations. A study found that guideline-based care may be cost-saving or cost-effective in most circumstances.³⁵⁰ The quality and usefulness of reviewed studies for decision making varied, however they concluded that with better information and higher-quality economic evaluations decision makers will have increased confidence to promote guideline-based care.³⁵⁰ With this in mind, a Danish study has advocated that by adopting a national strategy based on best practice guidelines, it may be possible to reduce the costs of wound management by 30%.³⁵¹

A delay in diagnosis of an atypical wound can occur as a result of limited access to specialist treatment and varying levels of expertise, skill set and knowledge. Significant savings have been demonstrated in some studies by the adoption of evidence-based care, such as that provided by the community and outpatient specialist wound clinics.³²⁵ Education, training and credentialing of health professionals in the management of chronic wounds is an indirect expense that must be factored into organisational budgets when evaluating costs and providing sufficient resources and cost-effective wound care.³²⁵

Implementing best practice guidelines developed by professional bodies, such as EWMA, and ensuring that those involved in the provision of wound care are educated appropriately, could have a significant impact on the financial burden of wound care. Potentially, the greatest efficiency gains can be achieved through effective training and education of health professionals; involved in wound care. A structured programme of training and providing credentials for health professionals involved in wound care, supported by best practice guideline and protocols, has real potential to reduce the variation in practice, reduce costs and improve patient outcomes.³⁵²⁻³⁵⁴

Cost to the patient

Finally, it's important to remember the role of the patient in the cost of managing their wound. A total estimate of the financial cost to the patient is unknown. The burden of these wounds and the direct impact on the patient and their family is often underestimated. Atypical wounds are often a symptom or complication of other comorbidities, affecting all age groups and can be life-long. Treatment pathways are often confusing and complex with multiple specialities managing the wound, resulting in cost of additional travel, absence from work, numerous diagnostic tests and

payment to specialists. Chronic wounds severely reduce QoL and patient wellbeing, capacity to work and increase social isolation.

Depending on the financial support and access to wound care services and wound products, they can also impose substantial personal costs to the patient. The trend towards delivery of wound care in the community has transferred the care costs from the

health system to the patient in countries that do not reimburse community-based care expenses. Costs for the patient such as travel expenses for domiciliary visits, wound dressings and compression bandages can be significant and may comprise their care decisions. Furthermore, these additional factors confound direct comparisons of health-care expenditure on wound management across health-care systems, and over time.

16. Conclusions and future perspectives

A typical wounds are estimated to comprise about 20% of all chronic wounds.³⁻⁵ There is a high demand on prospective multicentre clinical trials with well-defined outcomes. Following an extensive literature search clinical trials in the field of atypical wounds are scarce, with many reports' retrospective or case studies. In case of PG, there are two prospective randomised trials; one compared infliximab with placebo during an observation period of two weeks, and due to the superiority of infliximab in terms of clinical improvement (46% versus 6%), after these two weeks the non-responders in placebo group received also infliximab.³⁵

The other compared in a multicentre trial with 112 participants the efficacy of cyclosporin and prednisolone. Cyclosporin and prednisolone did not differ across a range of objectives and patient reported outcomes.³⁴ RCTs in the case of calciphylaxis are also under way. However future trials to compare new treatments, such as biologic drugs, head-to-head with prednisolone or cyclo-sporin are needed.²⁵³ While there is research currently in progress this author group recommend future projects incorporating atypical wounds should include the following:

1. In future trials recommended outcomes would be speed of healing time (for instance at six weeks), time to healing, patient reported pain, health related quality of life, adverse reactions to study drugs and complications such as infection, cellulitis, sepsis and death.³⁴

2. The exact pathophysiological mechanisms of many of these inflammatory wounds are still unknown. To tailor new targeted therapies in the pipeline both for drug and local therapies we need more precise understanding of the inflammatory and occlusive mechanisms of these wounds. For instance, we still lack a treatment that could specifically reduce subcutaneous arteriosclerosis.

3. There is evidence of a positive outcome to early skin grafting in ulcers in the context of arteriopathy, with a breakdown in the vicious cycle necrosis-inflammation and consequent pain reduction and epithelialisation promotion.¹⁴⁶ In contrast to the traditional concept of waiting for a suitable wound bed is present before grafting, healing stimulation may be observed without previous surgical, debridement, even if the wound bed presents with slough.¹⁴⁴ Consequently, it would be interesting to study the exact mediators involved in this phenomenon.

4. Since any non-healing wound, regardless of its aetiology, is an inflammatory lesion, the benefits of traditional treatments, such as topical corticosteroids and tacrolimus, should be studied further as new anti-inflammatory treatments are urgently needed. An imbalance between pro-inflammatory and anti-inflammatory macrophage phenotypes play an important role, so these cells should be the target of new treatment strategies.³⁵⁵ Considering the potential anti-inflammatory effect of skin grafting in wound healing, it should be studied how keratinocytes and molecules typically

involved in the final phase of epithelialisation may regulate the microenvironment of an abnormally prolonged inflammatory phase and accelerate wound healing. Studies could analyse the benefits of early punch grafting, which is a simple and cost-effective technique to enhance wound healing. Also, prospective studies on NPWT and advanced therapies would provide more strong evidence for treatment outcomes and reimbursement.

5. Another challenge for the management of atypical wounds is the lack of consensus and guidelines for the standardisation of treatment and the lack of economic studies. Moreover, most research in the area of atypical wound management is currently focused on wound outcomes during the wound-healing phase without taking into consideration the high rate of recurrences. It is recommended that the time of recurrence for ulcers, as well as their frequency, should also be taken into consideration when examining the effectiveness of treatments. Studies on the diagnostic delays would be important both for a patient's and an organisational point of view. In addition, cost efficacy is very seldom covered in studies concerning atypical wounds. For clinicians prompt diagnosis leads to better treatment results, but for advocacy it is important to show these facts in reliable figures.

6. Atypical wounds challenge the clinician both in recognition, diagnosis and treatment. It is not only important to broaden the knowledge of health professionals of these wounds, but also to establish specialised centres to treat the most challenging atypical wounds patients. Organised MDTs consisting of dermatologists, vascular and plastic surgeons, rheumatologists, diabetologists, infectious disease specialists, psychiatrists, tissue viability nurses, podiatrist, nephrologist, psychologists, nutritionists, physiotherapists and social care workers should be included in care pathways for these wounds.

Finally, we want again to emphasise the importance of early suspicion and expert consultation with these wounds. The 'wait and see'– attitude can lead to devastating outcomes. We hope the algorithm helps in daily practice in the systematic assessment of these wounds and that the document will be disseminated and used among all health professionals treating chronic wounds. We also hope that the document stimulates practitioners and scientists for a translational research approach in the future. Lastly, we would like to acknowledge all the feedback and comments we received from professionals all over the World. We are sincerely grateful for all your comments in order to ensure that this document is of great quality and will benefit both clinicians and patients.

17. References

1. Health Service Executive. Multidiscip. Team Health Serv. Exec. (2013)
2. Wiecha J, Pollard T. The interdisciplinary eHealth team: chronic care for the future. *J Med Internet Res* 2004; 6(3):e22. <https://dx.doi.org/10.2196%2Fjmir.6.3.e22>
3. Shanmugam VK, Angra D, Rahimi H, McNish S. Vasculitic and autoimmune wounds. *J Vasc Surg Venous Lymphat Disord* 2017; 5(2):280–292. <https://dx.doi.org/10.1016/j.jvs.2016.09.006>
4. Shanmugam VK, Schilling A, Germinario A et al. Prevalence of immune disease in patients with wounds presenting to a tertiary wound healing centre. *Int Wound J* 2012; 9(4):403–411. <https://dx.doi.org/10.1111/ij.1742-481X.2011.00899.x>
5. Körber A, Klode J, Al-Benna S et al. Etiology of chronic leg ulcers in 31,619 patients in Germany analyzed by an expert survey. *JDDG: Journal der Deutschen Dermatologischen Gesellschaft* 2011; 9(2):116–121. <https://dx.doi.org/10.1111/ij.1610-0387.2010.07535.x>
6. Shelling ML, Federman DG, Kirsner RS. Clinical approach to atypical wounds with a new model for understanding hypertensive ulcers. *Arch Dermatol* 2010; 146(9):1026–1029. <https://dx.doi.org/10.1001/archdermatol.2010.213>
7. Hoffman MD. Atypical ulcers. *Dermatol Ther* 2013; 26(3):222–235. <https://dx.doi.org/10.1111/dth.12048>
8. Mooij MC, Huisman LC. Chronic leg ulcer: does a patient always get a correct diagnosis and adequate treatment? *Phlebology* 2016; 31(1 suppl):68–73. <https://dx.doi.org/10.1177/0268355516632436>
9. Alavi A, Sibbald RG, Phillips TJ et al. What's new: Management of venous leg ulcers. *J Am Acad Dermatol* 2016; 74(4):627–640. <https://dx.doi.org/10.1016/j.jaad.2014.10.048>
10. Hradil E, Jeppsson C, Hamnerius N, Svensson Å. The diagnosis you wish you had never operated on: Pyoderma gangrenosum misdiagnosed as necrotizing fasciitis—a case report. *Acta Orthop* 2017; 88(2):231–233. <https://dx.doi.org/10.1080/17453674.2016.1260403>
11. Janowska A, Oranges T, Chiricozzi A et al. Synergism of Therapies After Postoperative Autograft Failure in a Patient With Melanoma of the Foot Misdiagnosed as a Pressure Ulcer. *Wounds* 2018; 30(4):E41–E43
12. Langan SM, Groves RW, Card TR, Gulliford MC. Incidence, mortality, and disease associations of pyoderma gangrenosum in the United Kingdom: a retrospective cohort study. *J Invest Dermatol* 2012; 132(9):2166–2170. <https://dx.doi.org/10.1038/jid.2012.130>
13. García-Lozano JA, Ocampo-Candiani J, Martínez-Cabriales SA, Garza-Rodríguez V. An Update on Calciphylaxis. *Am J Clin Dermatol* 2018; 19(4):599–608. <https://dx.doi.org/10.1007/s40257-018-0361-x>
14. Jones B, Lake A, Harper C. My wound and I: patients' perspective. *J Vis Commun Med* 2016; 39(3-4):120–126. <https://dx.doi.org/10.1080/17453054.2016.1246060>
15. Solowiej K, Mason V, Upton D. Review of the relationship between stress and wound healing: part 1. *J Wound Care* 2009; 18(9):357–366. <https://dx.doi.org/10.12968/jowc.2009.18.9.44302>
16. Tiri H, Huilaja L, Jokelainen J et al. Women with Hidradenitis Suppurativa Have an Elevated Risk of Suicide. *J Invest Dermatol* 2018; 138(12):2672–2674. <https://dx.doi.org/10.1016/j.jid.2018.06.171>
17. Al Ghazal P, Herberger K, Schaller J et al. Associated factors and comorbidities in patients with pyoderma gangrenosum in Germany: a retrospective multicentric analysis in 259 patients. *Orphanet J Rare Dis* 2013; 8(1):136. <https://dx.doi.org/10.1186/1750-1172-8-136>
18. Jockenhöfer F, Klode J, Kröger K et al. Patients with pyoderma gangrenosum - analyses of the German DRG data from 2012. *Int Wound J* 2016; 13(5):951–956. <https://dx.doi.org/10.1111/iwj.12463>
19. Wang EA, Steel A, Luxardi G et al. Classic Ulcerative Pyoderma Gangrenosum Is a T Cell-Mediated Disease Targeting Follicular Adnexal Structures: A Hypothesis Based on Molecular and Clinicopathologic Studies. *Front Immunol* 2018; 8:1980. <https://dx.doi.org/10.3389/fimmu.2017.01980>
20. Marzano AV, Borghi A, Meroni PL, Cugno M. Pyoderma gangrenosum and its syndromic forms: evidence for a link with autoinflammation. *Br J Dermatol* 2016; 175(5):882–891. <https://dx.doi.org/10.1111/bjd.14691>
21. Cugno M, Borghi A, Marzano AV. PAPA, PASH and PAPASH Syndromes: Pathophysiology, Presentation and Treatment. *Am J Clin Dermatol* 2017; 18(4):555–562. <https://dx.doi.org/10.1007/s40257-017-0265-1>
22. Cosgarea I, Lovric Z, Körber A, Dissemund J. Successful treatment of refractory pyoderma gangrenosum with ustekinumab only after excision of renal cell carcinoma. *Int Wound J* 2016; 13(5):1041–1042. <https://dx.doi.org/10.1111/iwj.12377>
23. Hadi A, Lebwohl M. Clinical features of pyoderma gangrenosum and current diagnostic trends. *J Am Acad Dermatol* 2011; 64(5):950–954. <https://dx.doi.org/10.1016/j.jaad.2010.01.049>
24. Herberger K, Dissemund J, Hohaus K et al. Treatment of pyoderma gangrenosum: retrospective multicentre analysis of 121 patients. *Br J Dermatol* 2016; 175(5):1070–1072. <https://dx.doi.org/10.1111/bjd.14619>
25. Barbosa NS, Tolkachjov SN, el-Azhary RA et al. Clinical features, causes, treatments, and outcomes of peristomal pyoderma gangrenosum (PPG) in 44 patients: The Mayo Clinic experience, 1996 through 2013. *J Am Acad Dermatol* 2016; 75(5):931–939. <https://dx.doi.org/10.1016/j.jaad.2016.05.044>
26. Zuo KJ, Fung E, Tredget EE, Lin AN. A systematic review of post-surgical pyoderma gangrenosum: Identification of risk factors and proposed management strategy. *J Plast Reconstr Aesthet Surg* 2015; 68(3):295–303. <https://dx.doi.org/10.1016/j.bjps.2014.12.036>
27. Larcher L, Schwaiger K, Eisele K et al. Aesthetic breast augmentation mastopexy followed by post-surgical pyoderma gangrenosum (pspg): clinic, treatment, and review of the literature. *Aesthetic Plast Surg* 2015; 39(4):506–513. <https://dx.doi.org/10.1007/s00266-015-0499-3>
28. André MF, Piette JC, Kémény JL et al.; French Study Group on Aseptic Abscesses. Aseptic Abscesses. *Medicine (Baltimore)* 2007; 86(3):145–161. <https://dx.doi.org/10.1097/md.0b013e1806449f3>
29. Jockenhöfer F, Wollina U, Salva KA et al. The PARACELSUS score: a novel diagnostic tool for pyoderma gangrenosum. *Br J Dermatol* 2018; 10.1111/bjd.16401
30. Maverakis E, Ma C, Shinkai K et al. Diagnostic Criteria of Ulcerative Pyoderma Gangrenosum. *JAMA Dermatol* 2018; 154(4):461–466. <https://dx.doi.org/10.1001/jamadermatol.2017.5980>
31. Kutlubay Z, Tüzün Y, Wolf R. The pathology test as a diagnostic tool. *Skinmed* 2017; 15(2):97–104

32. Al Ghazal P, Dissemond J. Therapy of pyoderma gangrenosum in Germany: results of a survey among wound experts. *JDDG: Journal der Deutschen Dermatologischen Gesellschaft* 2015; 13(4):317–324. <https://dx.doi.org/10.1111/ddg.12585>
33. Partridge AC, Bai JW, Rosen CF et al. Effectiveness of systemic treatments for pyoderma gangrenosum: a systematic review of observational studies and clinical trials. *Br J Dermatol* 2018; 179(2):290–295. <https://dx.doi.org/10.1111/bjd.16485>
34. Ormerod AD, Thomas KS, Craig FE et al. Comparison of the two most commonly used treatments for pyoderma gangrenosum: results of the STOP GAP randomised controlled trial. *BMJ* 2015; 350 jun12 3:h2958. <https://dx.doi.org/10.1136/bmj.h2958>
35. Brooklyn TN, Dunnill MG, Shetty A et al. Infliximab for the treatment of pyoderma gangrenosum: a randomised, double blind, placebo controlled trial. *Gut* 2006; 55(4):505–509. <https://dx.doi.org/10.1136/gut.2005.074815>
36. Dissemond J, Assenheimer B, Engels P et al. M.O.I.S.T. - a concept for the topical treatment of chronic wounds. *JDDG* 2017; 15(4):443–445. <https://dx.doi.org/10.1111/ddg.13215>
37. Leiphart PA, Lam CC, Foulke GT. Suppression of pathergy in pyoderma gangrenosum with infliximab allowing for successful tendon debridement. *JAAD Case Rep* 2018; 4(1):98–100. <https://dx.doi.org/10.1016/j.jidcr.2017.08.009>
38. Strohal R, Dissemond J, Jordan O'Brien J et al. EWMA Document: Debridement: An updated overview and clarification of the principle role of debridement. *J Wound Care* 2013; 22(Suppl 1):S1–S49. <https://dx.doi.org/10.12968/jowc.2013.22.Suppl.1>
39. Seo HI, Lee HJ, Han KH. Hyperbaric oxygen therapy for pyoderma gangrenosum associated with ulcerative colitis. *Intest Res* 2018; 16(1):155–157. <https://dx.doi.org/10.5217/ir.2018.16.1.155>
40. Pichler M, Thuile T, Gatscher B et al. Systematic review of surgical treatment of pyoderma gangrenosum with negative pressure wound therapy or skin grafting. *J Eur Acad Dermatol Venereol* 2017; 31(2):e61–e67. <https://dx.doi.org/10.1111/jdv.13727>
41. Dissemond J, Storck M, Kröger K, Stücker M. [Indications and contraindications for modern compression therapy]. [Article in German]. *Wien Med Wochenschr* 2018; 168(9–10):228–235. <https://dx.doi.org/10.1007/s10354-017-0605-z>
42. Wilkes SR, Williams HC, Ormerod AD et al. Is speed of healing a good predictor of eventual healing of pyoderma gangrenosum? *J Am Acad Dermatol* 2016; 75(6):1216–1220.e2. <https://dx.doi.org/10.1016/j.jaad.2016.07.049>
43. Jennette JC, Falk RJ, Bacon PA et al. 2012 Revised International Chapel Hill Consensus Conference Nomenclature of Vasculitides. *Arthritis Rheum* 2013; 65(1):1–11. <https://dx.doi.org/10.1002/art.37715>
44. Linos K, Cribier B, Carlson J. Cutaneous cryoglobulinemic vasculitis. In: *Dammacco F: HCV infection and cryoglobulinemia*. Springer-Verl, 2012
45. Ramos-Casals M, Stone JH, Cid MC, Bosch X. The cryoglobulinaemias. *Lancet* 2012; 379(9813):348–360. [https://dx.doi.org/10.1016/S0140-6736\(11\)60242-0](https://dx.doi.org/10.1016/S0140-6736(11)60242-0)
46. Terrier B, Karras A, Kahn JE et al. The spectrum of type I cryoglobulinemia vasculitis: new insights based on 64 cases. *Medicine (Baltimore)* 2013; 92(2):61–68. <https://dx.doi.org/10.1097/MD.0b013e318288925c>
47. Sunderkötter CH et al. Nomenclature of Cutaneous Vasculitis: Dermatologic Addendum to the 2012 Revised International Chapel Hill Consensus Conference Nomenclature of Vasculitides. *Arthritis Rheumatol*. Hoboken NJ 70, 171–184 (2018)
48. Yus ES, Simón RS, Requena L. Vein, artery, or arteriole? A decisive question in hypodermal pathology. *Am J Dermatopathol* 2012; 34(2):229–232. <https://dx.doi.org/10.1097/DAD.0b013e3182157ed1>
49. Criado PR, Marques GF, Morita TC, de Carvalho JF. Epidemiological, clinical and laboratory profiles of cutaneous polyarteritis nodosa patients: Report of 22 cases and literature review. *Autoimmun Rev* 2016; 15(6):558–563. <https://dx.doi.org/10.1016/j.autrev.2016.02.010>
50. Carlson JA, Chen KR. Cutaneous vasculitis update: neutrophilic muscular vessel and eosinophilic, granulomatous, and lymphocytic vasculitis syndromes. *Am J Dermatopathol* 2007; 29(1):32–43. <https://dx.doi.org/10.1097/01.dad.0000245198.80847.ff>
51. Sunderkötter C, de Groot K. [Therapy of vasculitis and vasculopathies]. [Article in German]. *Hautarzt* 2008; 59(5):382–393. <https://dx.doi.org/10.1007/s00105-008-1530-2>
52. Yang YH, Yu HH, Chiang BL. The diagnosis and classification of Henoch–Schönlein purpura: An updated review. *Autoimmun Rev* 2014; 13(4-5):355–358. <https://dx.doi.org/10.1016/j.autrev.2014.01.031>
53. Heineke MH, Ballering AV, Jamin A et al. New insights in the pathogenesis of immunoglobulin A vasculitis (Henoch–Schönlein purpura). *Autoimmun Rev* 2017; 16(12):1246–1253. <https://dx.doi.org/10.1016/j.autrev.2017.10.009>
54. Sunderkötter C. Vasculitis of small blood vessels - some riddles about IgA and about the complexity of transmigration. *Exp Dermatol* 2009; 18(1):91–96. <https://dx.doi.org/10.1111/j.1600-0625.2008.00791.x>
55. Sunderkötter C, Seeliger S, Schönlau F et al. Different pathways leading to cutaneous leukocytoclastic vasculitis in mice. *Exp Dermatol* 2001 Dec; 10(6):391–404. <https://dx.doi.org/10.1034/j.1600-0625.2001.100602.x>
56. Sindrilaru A, Seeliger S, Ehrchen JM et al. Site of blood vessel damage and relevance of CD18 in a murine model of immune complex-mediated vasculitis. *J Invest Dermatol* 2007; 127(2):447–454. <https://dx.doi.org/10.1038/sj.jid.5700563>
57. Requena L, Kutzner H, Angulo J, Renedo G. Generalized livedo reticularis associated with monoclonal cryoglobulinemia and multiple myeloma. *J Cutan Pathol* 2007; 34(2):198–202. <https://dx.doi.org/10.1111/j.1600-0560.2006.00594.x>
58. Braverman IM, Yen A. Demonstration of immune complexes in spontaneous and histamine-induced lesions and in normal skin of patients with leukocytoclastic angitis. *J Invest Dermatol* 1975; 64(2):105–112. <https://dx.doi.org/10.1111/1523-1747.ep12510321>
59. Gower RG, Mitchell Sams W Jr et al. Leukocytoclastic vasculitis: sequential appearance of immunoreactants and cellular changes in serial biopsies. *J Invest Dermatol* 1977; 69(5):477–484. <https://dx.doi.org/10.1111/1523-1747.ep12511631>
60. Arora A, Wetter DA, Gonzalez-Santiago TM et al. Incidence of leukocytoclastic vasculitis, 1996 to 2010: a population-based study in Olmsted County, Minnesota. *Mayo Clin Proc* 2014; 89(11):1515–1524. <https://dx.doi.org/10.1016/j.mayocp.2014.04.015>
61. García-Porrúa C, González-Gay MA. Comparative clinical and

- epidemiological study of hypersensitivity vasculitis versus Henoch-Schönlein purpura in adults. *Semin Arthritis Rheum* 1999; 28(6):404–412. [https://dx.doi.org/10.1016/S0049-0172\(99\)80006-7](https://dx.doi.org/10.1016/S0049-0172(99)80006-7)
62. Sunderkötter C, Bonsmann G, Sindrilaru A, Luger T. Management of leukocytoclastic vasculitis. *J Dermatolog Treat* 2005; 16(4):193–206. <https://dx.doi.org/10.1080/09546630500277971>
 63. Schroeter AL, Conn DL, Jordon RE. Immunoglobulin and complement deposition in skin of rheumatoid arthritis and systemic lupus erythematosus patients. *Ann Rheum Dis* 1976; 35(4):321–326. <https://dx.doi.org/10.1136/ard.35.4.321>
 64. Chen KR, Toyohara A, Suzuki A, Miyakawa S. Clinical and histopathological spectrum of cutaneous vasculitis in rheumatoid arthritis. *Br J Dermatol* 2002; 147(5):905–913. <https://dx.doi.org/10.1046/j.1365-2133.2002.04933.x>
 65. Ramos-Casals M, Nardi N, Lagrutta M et al. Vasculitis in systemic lupus erythematosus: prevalence and clinical characteristics in 670 patients. *Medicine (Baltimore)* 2006; 85(2):95–104. <https://dx.doi.org/10.1097/01.md.0000021681.17.35937.70>
 66. Yates M, Watts R. ANCA-associated vasculitis. *Clin Med (Northfield Ill)* 2017; 17(1):60–64. <https://dx.doi.org/10.7861/clinmedicine.17-1-60>
 67. K. Krumbholz M, Schönernermark U, Back W et al. Netting neutrophils in autoimmune small-vessel vasculitis. *Nat Med* 2009; 15(6):623–625. <https://dx.doi.org/10.1038/nm.1959>
 68. Chen KR. Skin involvement in ANCA-associated vasculitis. *Clin Exp Nephrol* 2013; 17(5):676–682. <https://dx.doi.org/10.1007/s10157-012-0736-x>
 69. Geetha D, Jin Q, Scott J, Hruskova Z et al. Comparisons of Guidelines and Recommendations of Managing Antineutrophil Cytoplasmic Antibody-Associated Vasculitis. *Kidney Int Rep* 2018; 3(5):1039–1049. <https://dx.doi.org/10.1016/j.ekir.2018.05.007>
 70. Schirmer JH, Aries PM, de Groot K et al. SI guidelines Diagnostics and treatment of ANCA-associated vasculitis. *Z Rheumatol* 2017; 76(S3 Suppl 3):77–104. <https://dx.doi.org/10.1007/s00393-017-0394-1>
 71. Segura S, Pujol RM, Trindade F, Requena L. Vasculitis in erythema induratum of Bazin: A histopathologic study of 101 biopsy specimens from 86 patients. *J Am Acad Dermatol* 2008; 59(5):839–851. <https://dx.doi.org/10.1016/j.jaad.2008.07.030>
 72. Llamas-Velasco M, Alegría V, Santos-Briz Á et al. Occlusive Nonvasculitic Vasculopathy. *Am J Dermatopathol* 2017; 39(9):637–662. <https://dx.doi.org/10.1097/DAD.0000000000000766>
 73. Carlson JA, Chen KR. Cutaneous Pseudovasculitis. *Am J Dermatopathol* 200729(1):44–55. <https://dx.doi.org/10.1097/01.dad.00000245195.35106.3c>
 74. Ehrmann S. [A new vascular symptom of syphilis.] *Wien Med Wochenschr* 1907; 57:777–782
 75. Lie JT. Cholesterol atheromatous embolism. The great masquerader revisited. *Pathol Annu* 1992; 27(Pt 2):17–50
 76. Ghanem F, Vodnala D, K Kalavakunta J et al. Cholesterol crystal embolization following plaque rupture: a systemic disease with unusual features. *J Biomed Res* 2017; 31(2):82–94
 77. Marneros AG, Blanco F, Husain S et al. Classification of cutaneous intravascular breast cancer metastases based on immunolabeling for blood and lymph vessels. *J Am Acad Dermatol* 2009; 60(4):633–638. <https://dx.doi.org/10.1016/j.jaad.2008.11.008>
 78. Lugassy C, Zadrán S, Bentolilla LA et al. Angiotropism, pericytic mimicry and extravascular migratory metastasis in melanoma: an alternative to intravascular cancer dissemination. *Cancer Microenviron* 2014; 7(3):139–152. <https://dx.doi.org/10.1007/s12307-014-0156-4>
 79. Alcaraz I, Ceroni L, Rütten A et al. Cutaneous metastases from internal malignancies: a clinicopathologic and immunohistochemical review. *Am J Dermatopathol* 2012; 34(4):347–393. <https://dx.doi.org/10.1097/DAD.0b013e31823069cf>
 80. Vinson RP, Chung A, Elston DM, Keller RA. Septic microemboli in a Janeway lesion of bacterial endocarditis. *J Am Acad Dermatol* 1996; 35(6):984–985. [https://dx.doi.org/10.1016/S0190-9622\(96\)90125-5](https://dx.doi.org/10.1016/S0190-9622(96)90125-5)
 81. Alpert JS. Osler's nodes and Janeway lesions are not the result of small-vessel vasculitis. *Am J Med* 2013; 126(10):843–844. <https://dx.doi.org/10.1016/j.amjmed.2013.04.002>
 82. Delgado-Jiménez Y, Fraga J, Fernández-Herrera J, García-Diez A. [Septic vasculopathy] *Actas Dermo-Sifiliograficas* 2007; 98(Suppl 1):22–28
 83. Habib G, Lancellotti P, Antunes MJ et al. 2015 ESC Guidelines for the management of infective endocarditis. *Eur Heart J* 2015; 36(44):3075–3128. <https://dx.doi.org/10.1093/eurheartj/ehv319>
 84. Prechel M, Walenga J. Heparin-induced thrombocytopenia: an update. *Semin Thromb Hemost* 2012; 38(05):483–496. <https://dx.doi.org/10.1055/s-0032-1306432>
 85. Cacoub P, Comarmond C, Domont F et al. Cryoglobulinemia Vasculitis. *Am J Med* 2015; 128(9):950–955. <https://dx.doi.org/10.1016/j.amjmed.2015.02.017>
 86. Ramirez GA, Campochiaro C, Salmaggi C et al. Bortezomib in type I cryoglobulinemic vasculitis: are we acting too late? *Intern Med* 2015; 54(9):1119–1123. <https://dx.doi.org/10.2169/internalmedicine.54.3668>
 87. Gupta V, El Ters M, Kashani K et al. Crystalglobulin-Induced Nephropathy. *J Am Soc Nephrol* 2015; 26(3):525–529. <https://dx.doi.org/10.1681/ASN.2014050509>
 88. Nazarian RM, Van Cott EM, Zembowicz A, Duncan LM. Warfarin-induced skin necrosis. *J Am Acad Dermatol* 2009; 61(2):325–332. <https://dx.doi.org/10.1016/j.jaad.2008.12.039>
 89. Fred HL. Skin Necrosis Induced by Coumarin Congeners. *Tex Heart Inst J* 2017; 44(4):233–236. <https://dx.doi.org/10.14503/THIJ-17-6430>
 90. Thornsberry LA, LoSicco KI, English JC 3rd. The skin and hypercoagulable states. *J Am Acad Dermatol* 2013; 69(3):450–462. <https://dx.doi.org/10.1016/j.jaad.2013.01.043>
 91. Watt SG, Winhoven S, Hay CR, Lucas GS. Purpura fulminans in paroxysmal nocturnal haemoglobinuria. *Br J Haematol* 2007; 137(4):271. <https://dx.doi.org/10.1111/j.1365-2141.2007.06522.x>
 92. Chalmers E, Cooper P, Forman K et al. Purpura fulminans: recognition, diagnosis and management. *Arch Dis Child* 2011; 96(11):1066–1071. <https://dx.doi.org/10.1136/adc.2010.199919>
 93. Milstone LM, Braverman IM. PURPLE (oops! Atrophie blanche) revisited. *Arch Dermatol* 1998; 134(12):1634–1634. <https://dx.doi.org/10.1001/archderm.134.12.1634>
 94. Llamas-Velasco M, de Argila D, Fraga J, García-Diez A. Cutaneous polyarteritis nodosa with manifestations of livedoid vasculopathy. *Actas Dermo-Sifiliograficas Engl. Ed.* 102, 477–479 (2011).
 95. Mimouni D, Ng PP, Rencic A et al. Cutaneous polyarteritis nodosa in patients presenting with atrophie blanche. *Br J Dermatol* 2003; 148(4):789–794. <https://dx.doi.org/10.1046/j.1365-2133.2003.05176.x>
 96. Alavi A, Hafner J, Dutz JP et al. Livedoid vasculopathy: An in-depth analysis using a modified Delphi approach. *J Am Acad Dermatol* 2013; 69(6):1033–1042.e1. <https://dx.doi.org/10.1016/j.jaad.2013.07.019>
 97. Vasudevan B, Neema S, Verma R. Livedoid vasculopathy: A review of pathogenesis and principles of management. *Indian J Dermatol Venereol Leprol* 2016; 82(5):478–488. <https://dx.doi.org/10.4103/0378-6323.183635>
 98. Franco Marques G, Criado PR, Alves Batista Morita TC, Cajas García MS. The management of livedoid vasculopathy focused on direct oral anticoagulants (DOACs): four case reports successfully treated with rivaroxaban. *Int J Dermatol* 2018; 57(6):732–741. <https://dx.doi.org/10.1111/ijd.13997>
 99. Micieli R, Alavi A. Treatment for Livedoid Vasculopathy. *JAMA Dermatol* 2018; 154(2):193–202. <https://dx.doi.org/10.1001/jamadermatol.2017.4374>
 100. Hafner J. Calciphylaxis and Martorell hypertensive ischemic leg ulcer: same pattern - one pathophysiology. *Dermatology* 2016; 232(5):523–533. <https://dx.doi.org/10.1159/000448245>
 101. Bertranou EG, Gonoraky SE, Otero AE. [Martorell hypertensive arteriolar ulcer: Outpatient outcome on 366 cases]. [Articles in French] *Phlebologie* 2001; 54:267–272

- 102.** Hafner J, Keusch G, Wahl C, Burg G. Calciphylaxis: a syndrome of skin necrosis and acral gangrene in chronic renal failure. *Vasa* 1998; 27(3):137–143
- 103.** Hafner J, Nobbe S, Partsch H et al. Martorell hypertensive ischemic leg ulcer: a model of ischemic subcutaneous arteriolosclerosis. *Arch Dermatol* 2010; 146(9):961–968. <https://dx.doi.org/10.1001/archdermatol.2010.224>
- 104.** Nigwekar SU, Thadhani R, Brandenburg VM. Calciphylaxis. *N Engl J Med* 2018; 378(18):1704–1714. <https://dx.doi.org/10.1056/NEJMra1505292>
- 105.** Schnier BR, Sheps SG, Juergens JL. Hypertensive ischemic ulcer. *Am J Cardiol* 1966; 17(4):560–565. [https://dx.doi.org/10.1016/0002-9149\(66\)90247-5](https://dx.doi.org/10.1016/0002-9149(66)90247-5)
- 106.** Senet P, Beneton N, Debure C et al. [Hypertensive leg ulcers: epidemiological characteristics and prognostic factors for healing in a prospective cohort]. [Article in French] *Ann Dermatol Venereol* 2012; 139(5):346–349. <https://dx.doi.org/10.1016/j.annder.2011.09.191>
- 107.** Strazzula L, Nigwekar SU, Steele D et al. Intralesional sodium thiosulfate for the treatment of calciphylaxis. *JAMA Dermatol* 2013; 149(8):946–949. <https://dx.doi.org/10.1001/jamadermatol.2013.4565>
- 108.** Kalajian AH, Malhotra PS, Callen JP, Parker LP. Calciphylaxis with normal renal and parathyroid function: not as rare as previously believed. *Arch Dermatol* 2009; 145(4):451–458. <https://dx.doi.org/10.1001/archdermatol.2008.602>
- 109.** Nigwekar SU, Wolf M, Sterns RH, Hix JK. Calciphylaxis from nonuremic causes: a systematic review. *Clin J Am Soc Nephrol* 2008; 3(4):1139–1143. <https://dx.doi.org/10.2215/CJN.00530108>
- 110.** Ramsey-Stewart G. Eutrophication: spontaneous progressive dermatoliponecrosis, a fatal complication of gross morbid obesity. *Obes Surg* 1992; 2(3):263–264. <https://dx.doi.org/10.1381/096089292765560141>
- 111.** Martorell F. [Supra-malleolar ulcers secondary to arteriolitis among women with uncontrolled hypertension]. *Actas Reun Cientif Cuerpo Facul Inst Policlin Barc* 1945; 1(1):6–9
- 112.** Vuerstaek JD, Reeder SW, Henquet CJ, Neumann HA. Arteriolosclerotic ulcer of Martorell. *J Eur Acad Dermatol Venereol* 2010; 24(8):867–874. <https://dx.doi.org/10.1111/j.1468-3083.2009.03553.x>
- 113.** Santos PW, He J, Tuffaha A, Wetmore JB. Clinical characteristics and risk factors associated with mortality in calcific uremic arteriopathy. *Int Urol Nephrol* 2017; 49(12):2247–2256. <https://dx.doi.org/10.1007/s11255-017-1721-9>
- 114.** Lazareth I, Priollet P. [Necrotic angiodermatitis: treatment by early cutaneous grafts]. [Article in French] *Ann Dermatol Venereol* 1995; 122(9):575–578
- 115.** Nicol P, Bernard P, Nguyen P, et al. [Retrospective study of hypertensive leg ulcers at Reims University Hospital: Epidemiological, clinical, disease progression data, effects of vitamin K antagonists]. [Article in French] *Ann Dermatol Venereol* 2017; 144(1):37–44. <https://dx.doi.org/10.1016/j.annder.2016.09.039>
- 116.** Priollet P, Juillet Y, Grill S, Phat VN, Housset E. [Necrotic angiodermatitis]. [Article in French] *Ann Dermatol Venereol* 1984; 111(1):55–61
- 117.** Senet P, Vicaut E, Beneton N et al. Topical treatment of hypertensive leg ulcers with platelet-derived growth factor-BB: a randomized controlled trial. *Arch Dermatol* 2011; 147(8):926–930. <https://dx.doi.org/10.1001/archdermatol.2011.84>
- 118.** Brandenburg VM, Kramann R, Rothe H et al. Calcific uremic arteriopathy (calciphylaxis): data from a large nationwide registry. *Nephrol. Dial. Transplant. Off. Publ. Eur. Dial. Transpl. Assoc. - Eur Ren Assoc* 2017; 32:126–132. <https://doi.org/10.1093/ndt/gfv438>
- 119.** Nigwekar SU, Zhao S, Wenger J et al. A Nationally Representative Study of Calcific Uremic Arteriopathy Risk Factors. *J Am Soc Nephrol* 2016; 27(11):3421–3429. <https://dx.doi.org/10.1681/ASN.2015091065>
- 120.** Griethe W, Schmitt R, Jurgensen JS et al. Bone morphogenic protein-4 expression in vascular lesions of calciphylaxis. *J Nephrol* 2003; 16(5):728–732
- 121.** Nigwekar SU, Bloch DB, Nazarian RM et al. Vitamin K-Dependent Carboxylation of Matrix Gla Protein Influences the Risk of Calciphylaxis. *J Am Soc Nephrol* 2017; 28(6):1717–1722. <https://dx.doi.org/10.1681/ASN.2016060651>
- 122.** Schäfer C, Heiss A, Schwarz A et al. The serum protein α 2-Heremans-Schmid glycoprotein/fetuin-A is a systemically acting inhibitor of ectopic calcification. *J Clin Invest* 2003; 112(3):357–366. <https://dx.doi.org/10.1172/JCI17202>
- 123.** Schurgers LJ, Uitto J, Reutelingsperger CP. Vitamin K-dependent carboxylation of matrix Gla-protein: a crucial switch to control ectopic mineralization. *Trends Mol Med* 2013; 19(4):217–226. <https://dx.doi.org/10.1016/j.molmed.2012.12.008>
- 124.** Mikhaylova L, Malmquist J, Nurminskaya M. Regulation of in vitro vascular calcification by BMP4, VEGF and Wnt3a. *Calcif Tissue Int* 2007; 81(5):372–381. <https://dx.doi.org/10.1007/s00223-007-9073-6>
- 125.** Farber EM, Hines EA Jr, Montgomery H, Craig WM. The arterioles of the skin in essential hypertension. *J Invest Dermatol* 1947; 9(6):285–298. <https://dx.doi.org/10.1038/jid.1947.101> Medline
- 126.** Hafner J, Keusch G, Wahl C et al. Uremic small-artery disease with medial calcification and intimal hyperplasia (so-called calciphylaxis): a complication of chronic renal failure and benefit from parathyroidectomy. *J Am Acad Dermatol* 1995; 33(6):954–962. [https://dx.doi.org/10.1016/0190-9622\(95\)90286-4](https://dx.doi.org/10.1016/0190-9622(95)90286-4)
- 127.** Chertow GM, Block GA, Correa-Rotter R et al. Effect of cinacalcet on cardiovascular disease in patients undergoing dialysis. *N Engl J Med* 2012; 367(26):2482–2494. <https://dx.doi.org/10.1056/NEJMoa1205624>
- 128.** Mawad HW, Sawaya BP, Sarin R, Malleche HH. Calcific uremic arteriopathy in association with low turnover uremic bone disease. *Clin Nephrol* 1999; 52(3):160–166
- 129.** Moe SM, Chen NX. Calciphylaxis and vascular calcification: a continuum of extra-skeletal osteogenesis. *Pediatr Nephrol* 2003; 18(10):969–975. <https://dx.doi.org/10.1007/s00467-003-1276-0>
- 130.** Nigwekar SU, Jiramongkolchai P, Wunderer F et al. Increased bone morphogenetic protein signaling in the cutaneous vasculature of patients with calciphylaxis. *Am J Nephrol* 2017; 46(5):429–438. <https://dx.doi.org/10.1159/000484418>
- 131.** Rothe H, Brandenburg V, Haun M et al. Ecto-5'-Nucleotidase CD73 (NT5E), vitamin D receptor and FGF23 gene polymorphisms may play a role in the development of calcific uremic arteriopathy in dialysis patients – data from the German Calciphylaxis Registry. *PLoS One* 2017; 12(2):e0172407. <https://dx.doi.org/10.1371/journal.pone.0172407>
- 132.** Shroff R, Long DA, Shanahan C. Mechanistic insights into vascular calcification in CKD. *J Am Soc Nephrol* 2013; 24(2):179–189. <https://dx.doi.org/10.1681/ASN.2011121191>
- 133.** Torregrosa JV, Sánchez-Escuredo A, Barros X et al. Clinical management of calcific uremic arteriopathy before and after therapeutic inclusion of bisphosphonates. *Clin Nephrol* 2015; 83(4):231–234
- 134.** Yamada S, Giachelli CM. Vascular calcification in CKD-MBD: Roles for phosphate, FGF23, and Klotho. *Bone* 2017; 100:87–93. <https://dx.doi.org/10.1016/j.bone.2016.11.012>
- 135.** Kolios AG, Hafner J, Luder C et al. Comparison of pyoderma gangrenosum and Martorell hypertensive ischaemic leg ulcer in a Swiss cohort. *Br J Dermatol* 2018; 178(2):e125–e126. <https://dx.doi.org/10.1111/bjd.15901>
- 136.** Ratzinger G, Zelger BG, Carlson JA et al. Vasculitic wheel - an algorithmic approach to cutaneous vasculitides. *JDDG* 2015; 13(11):1092–1117. <https://dx.doi.org/10.1111/ddg.12859>
- 137.** Vaiman M, Lazarovitch T, Heller L, Lotan G. Ecthyma gangrenosum and ecthyma-like lesions: review article. *Eur J Clin Microbiol Infect Dis* 2015; 34(4):633–639. <https://dx.doi.org/10.1007/s10096-014-2277-6>

138. Galloway PA, El-Damanawi R, Bardsley V et al. Vitamin K antagonists predispose to calciphylaxis in patients with end-stage renal disease. *Nephron* 2015; 129(3):197–201. <https://dx.doi.org/10.1159/000371449>
139. Knapen MH, Braam LA, Drummen NE et al. Menaquinone-7 supplementation improves arterial stiffness in healthy postmenopausal women. *Thromb Haemostasis* 2015; 113(05):1135–1144. <https://dx.doi.org/10.1160/TH14-08-0675>
140. Brandenburg VM, Reinartz S, Kaesler N et al. Slower progress of aortic valve calcification with vitamin K supplementation. *Circulation* 2017; 135(21):2081–2083. <https://dx.doi.org/10.1161/CIRCULATIONAHA.116.027011>
141. Nigwekar SU, Brunelli SM, Meade D et al. Sodium thiosulfate therapy for calcific uremic arteriopathy. *Clin J Am Soc Nephrol* 2013; 8(7):1162–1170. <https://dx.doi.org/10.2215/CJN.09880912>
142. Pillai IC, Li S, Romay M et al. Cardiac Fibroblasts Adopt Osteogenic Fates and Can Be Targeted to Attenuate Pathological Heart Calcification. *Cell Stem Cell* 2017; 20(2):218–232.e5. <https://dx.doi.org/10.1016/j.stem.2016.10.005>
143. Chen NX, O'Neill K, Akl NK, Moe SM. Adipocyte induced arterial calcification is prevented with sodium thiosulfate. *Biochem Biophys Res Commun* 2014; 449(1):151–156. <https://dx.doi.org/10.1016/j.bbrc.2014.05.005>
144. Conde Montero E, Guisado Muñoz S, Pérez Jerónimo L et al. Martorell Hypertensive Ischemic Ulcer Successfully Treated With Punch Skin Grafting. *Wounds* 2018; 30(2):E9–E12
145. Zitt E, König M, Vychytil A, Auinger M et al. Use of sodium thiosulfate in a multi-interventional setting for the treatment of calciphylaxis in dialysis patients. *Nephrol Dial Transplant* 2013; 28(5):1232–1240. <https://dx.doi.org/10.1093/ndt/gfs548>
146. Dagregorio G, Guillet G. A retrospective review of 20 hypertensive leg ulcers treated with mesh skin grafts. *J Eur Acad Dermatol Venereol* 2006; 20(2):166–169. <https://dx.doi.org/10.1111/j.1468-3083.2006.01399.x>
147. Velpeau A, A. [Medical dictionary, or general directory of medical sciences considered under the theoretical and practical report]. *Béchet Jeune* 30, (1839)
148. Jemec GB. Hidradenitis Suppurativa. *N Engl J Med* 2012; 366(2):158–164. <https://dx.doi.org/10.1056/NEJMc1014163>
149. Zouboulis CC, del Marmol V, Mrowietz U et al. Hidradenitis Suppurativa/Acne Inversa: Criteria for Diagnosis, Severity Assessment, Classification and Disease Evaluation. *Dermatology* 2015; 231(2):184–190. <https://dx.doi.org/10.1159/000431175>
150. Gasparic J, Theut Riis P, Jemec GB. Recognizing syndromic hidradenitis suppurativa: a review of the literature. *J Eur Acad Dermatol Venereol* 2017; 31(11):1809–1816. <https://dx.doi.org/10.1111/jdv.14464>
151. Thorlacius L, Cohen AD, Gislason GH et al. Increased Suicide Risk in Patients with Hidradenitis Suppurativa. *J Invest Dermatol* 2018; 138(1):52–57. <https://dx.doi.org/10.1016/j.jid.2017.09.008>
152. Egeberg A, Gislason GH, Hansen PR. Risk of Major Adverse Cardiovascular Events and All-Cause Mortality in Patients With Hidradenitis Suppurativa. *JAMA Dermatol* 2016; 152(4):429–434. <https://dx.doi.org/10.1001/jamadermatol.2015.6264>
153. Jemec GB, Kimball AB. Hidradenitis suppurativa: Epidemiology and scope of the problem. *J Am Acad Dermatol* 2015; 73(5 Suppl 1):S4–S7. <https://dx.doi.org/10.1016/j.jaad.2015.07.052>
154. Saunte DM, Boer J, Stratigos A et al. Diagnostic delay in hidradenitis suppurativa is a global problem. *Br J Dermatol* 2015; 173(6):1546–1549. <https://dx.doi.org/10.1111/bjd.14038>
155. Deckers IE, Jansse IC, van der Zee HH et al. Hidradenitis suppurativa (HS) is associated with low socioeconomic status (SES): A cross-sectional reference study. *J Am Acad Dermatol* 2016; 75(4):755–759. <https://dx.doi.org/10.1016/j.jaad.2016.04.067>
156. Theut Riis P, Pedersen OB, Sigsgaard V et al. Prevalence of patients with self-reported hidradenitis suppurativa in a cohort of Danish blood donors: a cross-sectional study. *Br J Dermatol* 2018; 10.1111/bjd.16998
157. Ralf Paus L, Kurzen H, Kurokawa I et al. What causes hidradenitis suppurativa? *Exp Dermatol* 2008; 17(5):455–472. <https://dx.doi.org/10.1111/j.1600-0625.2008.00712.x>
158. van der Zee HH, de Ruyter L, van den Broecke DG et al. Elevated levels of tumour necrosis factor (TNF)- α , interleukin (IL)-1 β and IL-10 in hidradenitis suppurativa skin: a rationale for targeting TNF- α and IL-1 β . *Br J Dermatol* 2011; 164(6):1292–1298. <https://dx.doi.org/10.1111/j.1365-2133.2011.10254.x>
159. Moran B, Sweeney CM, Hughes R et al. Hidradenitis suppurativa is characterized by dysregulation of the th17:reg cell axis, which is corrected by anti-TNF therapy. *J Invest Dermatol* 2017; 137(11):2389–2395. <https://dx.doi.org/10.1016/j.jid.2017.05.033>
160. Boer J, Weltevreden EF. Hidradenitis suppurativa or acne inversa. A clinicopathological study of early lesions. *Br J Dermatol* 1996; 135(5):721–725. <https://dx.doi.org/10.1111/j.1365-2133.1996.tb03880.x>
161. Ring H, Bay L, Kallenbach K et al. Normal skin microbiota is altered in pre-clinical hidradenitis suppurativa. *Acta Derm Venereol* 2017; 97(2):208–213. <https://dx.doi.org/10.2340/00015555-2503>
162. Jemec GB, Hansen U. Histology of hidradenitis suppurativa. *J Am Acad Dermatol* 1996; 34(6):994–999. [https://dx.doi.org/10.1016/S0190-9622\(96\)90277-7](https://dx.doi.org/10.1016/S0190-9622(96)90277-7)
163. Ring HC, Bay L, Nilsson M et al. Bacterial biofilm in chronic lesions of hidradenitis suppurativa. *Br J Dermatol* 2017; 176(4):993–1000. <https://dx.doi.org/10.1111/bjd.15007>
164. Mozeika E, Pilmane M, Nürnberg B, Jemec G. Tumour necrosis factor-alpha and matrix metalloproteinase-2 are expressed strongly in hidradenitis suppurativa. *Acta Derm Venereol* 2013; 93(3):301–304. <https://dx.doi.org/10.2340/00015555-1492>
165. Saunte DM, Jemec GB. Hidradenitis suppurativa. *JAMA* 2017; 318(20):2019–2032. <https://dx.doi.org/10.1001/jama.2017.16691>
166. Alavi A, Kirsner RS. Local wound care and topical management of hidradenitis suppurativa. *J Am Acad Dermatol* 2015; 73(5 Suppl 1):S55–S61. <https://dx.doi.org/10.1016/j.jaad.2015.07.048>
167. Kazemi A, Carnaggio K, Clark M et al. Optimal wound care management in hidradenitis suppurativa. *J Dermatol Treat* 2018; 29(2):165–167. <https://dx.doi.org/10.1080/09546634.2017.1342759>
168. Alavi A, Farzanfar D, Lee RK, Almutairi D. The Contribution of malodour in quality of life of patients with hidradenitis suppurativa. *J Cutan Med Surg* 2018; 22(2):166–174. <https://dx.doi.org/10.1177/1203475417745826>
169. Riis P, Vinding G, Ring H, Jemec G. Disutility in Patients with Hidradenitis Suppurativa: A cross-sectional study using EuroQoL-5D. *Acta Derm Venereol* 2016; 96(2):222–226. <https://dx.doi.org/10.2340/00015555-2129>
170. van der Zee HH, Prens EP, Boer J. Deroofing: A tissue-saving surgical technique for the treatment of mild to moderate hidradenitis suppurativa lesions. *J Am Acad Dermatol* 2010; 63(3):475–480. <https://dx.doi.org/10.1016/j.jaad.2009.12.018>
171. Morgan WP, Harding KG, Hughes LE. A comparison of skin grafting and healing by granulation, following axillary excision for hidradenitis suppurativa. *Ann R Coll Surg Engl* 1983; 65(4):235–236
172. Silverberg B, Smoot CE, Landa SJ, Parsons RW. Hidradenitis suppurativa. *Plast Reconstr Surg* 1987; 79(4):555–559. <https://dx.doi.org/10.1097/00006534-198704000-00007>
173. Elwood ET, Bolitho DG. Negative-pressure dressings in the treatment of hidradenitis suppurativa. *Ann Plast Surg* 2001; 46(1):49–51. <https://dx.doi.org/10.1097/0000637-200101000-00010>
174. Lächli S, Bayard I, Hafner J et al. [Different duration of healing and frequency of hospitalization in ulcer cruris of various causes]. [Article in German] *Hautarzt* 2013; 64(12):917–922. <https://dx.doi.org/10.1007/s00105-013-2671-5>

- 175.** Yang D, Morrison BD, Vandongen YK et al. Malignancy in chronic leg ulcers. *Med J Aust* 1996; 164(12):718–720
- 176.** Colgan MP, Moore DJ, Shanik GD. Challenges in diagnosis. *J Wound Care* 1998; 7(4):200–202. <https://dx.doi.org/10.12968/jowc.1998.7.4.200>
- 177.** Misciali C, Dika E, Fanti PA et al. Frequency of malignant neoplasms in 257 chronic leg ulcers. *Dermatol Surg* 2013; 39(6):849–854. <https://dx.doi.org/10.1111/dsu.12168>
- 178.** Combemale P, Combemale P, Debure C et al. Malignancy and chronic leg ulcers: the value of systematic wound biopsies: a prospective, multicenter, cross-sectional study. *Arch Dermatol* 2012; 148(6):704–708. <https://dx.doi.org/10.1001/archdermatol.2011.3362>
- 179.** Gilbody JS, Aitken J, Green A. What causes basal cell carcinoma to be the commonest cancer? *Aust J Public Health* 1994; 18(2):218–221. <https://dx.doi.org/10.1111/j.1753-6405.1994.tb00231.x>
- 180.** Miller DL, Weinstock MA. Nonmelanoma skin cancer in the United States: Incidence. *J Am Acad Dermatol* 1994; 30(5):774–778. [https://dx.doi.org/10.1016/S0190-9622\(08\)81509-5](https://dx.doi.org/10.1016/S0190-9622(08)81509-5)
- 181.** Staples MP, Elwood M, Burton RC et al. Non-melanoma skin cancer in Australia: the 2002 national survey and trends since 1985. *Med J Aust* 2006; 184(1):6–10
- 182.** Jensen P, Hansen S, Møller B et al. Skin cancer in kidney and heart transplant recipients and different long-term immunosuppressive therapy regimens. *J Am Acad Dermatol* 1999; 40(2):177–186. [https://dx.doi.org/10.1016/S0190-9622\(99\)70185-4](https://dx.doi.org/10.1016/S0190-9622(99)70185-4)
- 183.** Lindelöf B, Sigurgeirsson B, Gäbel H, Stern RS. Incidence of skin cancer in 5356 patients following organ transplantation. *Br J Dermatol* 2000; 143(3):513–519
- 184.** Que SK, Zwald FO, Schmults CD. Cutaneous squamous cell carcinoma. *J Am Acad Dermatol* 2018; 78(2):237–247. <https://dx.doi.org/10.1016/j.jaad.2017.08.059>
- 185.** Xiang F, Lucas R, Hales S, Neale R. Incidence of nonmelanoma skin cancer in relation to ambient UV radiation in white populations, 1978–2012: empirical relationships. *JAMA Dermatol* 2014; 150(10):1063–1071. <https://dx.doi.org/10.1001/jamadermatol.2014.762>
- 186.** Aloï F, Tomasini C, Margiotta A, Pippione M. Chronic venous stasis: not a predisposing factor for basal cell carcinoma on the leg. A histopathological study. *Dermatology* 1994; 188(2):91–93. <https://dx.doi.org/10.1159/000247108>
- 187.** Hannuksela-Svahn A, Pukkala E, Karvonen J. Basal cell carcinoma and other nonmelanoma skin cancers in Finland from 1956 through 1995. *Arch Dermatol* 1999; 135(7):781–786. <https://dx.doi.org/10.1001/archderm.135.7.781>
- 188.** Black MM, Walkden VM. Basal cell carcinomatous changes on the lower leg: a possible association with chronic venous stasis. *Histopathology* 1983; 7(2):219–227. <https://dx.doi.org/10.1111/j.1365-2559.1983.tb02237.x>
- 189.** Patel NP, Kim SH, Padberg FT Jr. Venous ulceration and basal cell carcinoma: coincident or synergistic? *J Vasc Surg* 2006 Jul; 44(1):210–210. <https://dx.doi.org/10.1016/j.jvs.2005.01.050> Medline
- 190.** Harris B, Eaglstein WH, Falanga V. Basal cell carcinoma arising in venous ulcers and mimicking granulation tissue. *J Dermatol Surg Oncol* 1993; 19(2):150–152. <https://dx.doi.org/10.1111/j.1524-4725.1993.tb03445.x>
- 191.** Baldursson B, Sigurgeirsson B, Lindelöf B. Venous leg ulcers and squamous cell carcinoma: a large-scale epidemiological study. *Br J Dermatol* 1995; 133(4):571–574. <https://dx.doi.org/10.1111/j.1365-2133.1995.tb02707.x>
- 192.** Kaplan RP. Cancer complicating chronic ulcerative and scarifying mucocutaneous disorders. *Adv Dermatol* 1987; 2:19–46 Medline.
- 193.** Da Costa JC 3rd. III. Carcinomatous Changes in an Area of Chronic Ulceration, or Marjolin's Ulcer. *Ann Surg* 1903; 37(4):496–502.
- 194.** Reich-Schupke S, Doerler M, Wollina U et al. Squamous cell carcinomas in chronic venous leg ulcers. Data of the German Marjolin Registry and review. *JDDG* 2015; 13(10):1006–1013. <https://dx.doi.org/10.1111/ddg.12649>
- 195.** Baldursson B, Sigurgeirsson B, Lindelöf B. Leg ulcers and squamous cell carcinoma. An epidemiological study and a review of the literature. *Acta Derm Venereol* 1993; 73(3):171–174
- 196.** Combemale P, Bousquet M, Kanitakis J et al. Malignant transformation of leg ulcers: a retrospective study of 85 cases. *J Eur Acad Dermatol Venereol* 2007; 21(7):935–941. <https://dx.doi.org/10.1111/j.1468-3083.2006.02118.x>
- 197.** Onesti MG, Fino P, Fioramonti P, et al. Ten years of experience in chronic ulcers and malignant transformation. *Int Wound J* 2015; 12(4):447–450. <https://dx.doi.org/10.1111/iwj.12134>
- 198.** Panuncialman J, Hammerman S, Carson P, Falanga V. Wound edge biopsy sites in chronic wounds heal rapidly and do not result in delayed overall healing of the wounds. *Wound Repair Regen* 2010; 18(1):21–25. <https://dx.doi.org/10.1111/j.1524-475X.2009.00559.x>
- 199.** Enoch S, Miller DR, Price PE, Harding KG. Early diagnosis is vital in the management of squamous cell carcinomas associated with chronic non healing ulcers: a case series and review of the literature. *Int Wound J* 2004; 1(3):165–175. <https://dx.doi.org/10.1111/j.1742-4801.2004.00056.x>
- 200.** Bonerandi JJ, Beauvillain C, Caquant L et al.; French Dermatology Recommendations Association (aRED). Guidelines for the diagnosis and treatment of cutaneous squamous cell carcinoma and precursor lesions. *J Eur Acad Dermatol Venereol* 2011; 25 Suppl 1:5–51. <https://dx.doi.org/10.1111/j.1468-3083.2011.04296.x>
- 201.** Breuninger H, Bootz F, Hauschild A, et al. Short German guidelines: Squamous cell carcinoma. *J Dtsch Dermatol Ges* 2008; 6 Suppl 1:55–58. <https://dx.doi.org/10.1111/j.1610-0387.2008.06706.x>
- 202.** Trent JT, Kirsner RS. Wounds and Malignancy. *Adv Skin Wound Care* 2003; 16(1):31–34. <https://dx.doi.org/10.1097/00129334-200301000-00014>
- 203.** Cecchi R, Bartoli L, Brunetti L. Double helix flaps for lower leg defects: Report of 4 cases. *J Cutan Aesthet Surg* 2013; 6(3):164–165. <https://dx.doi.org/10.4103/0974-2077.118425>
- 204.** Cecchi R, Bartoli L, Brunetti L, Troiano G. Reconstruction of a large leg defect with a combined hatchet flap technique. *Dermatol Online J* 2017; 23(4):
- 205.** Dixon AJ, Dixon MP. Reducing opposed multilobed flap repair; a new technique for managing medium-sized low-leg defects following skin cancer surgery. *Dermatol Surg* 2004; 30(11):1406–1411
- 206.** Verdolini R, Dhoat S, Bugatti L, Filosa G. Opposed bilateral transposition flap: a simple and effective way to close large defects, especially of the limbs. *J Eur Acad Dermatol Venereol* 2008; 22(5):601–605. <https://dx.doi.org/10.1111/j.1468-3083.2008.02696.x>
- 207.** Martinez JC, Cook JL, Otle C. The keystone fasciocutaneous flap in the reconstruction of lower extremity wounds. *Dermatol Surg* 2012; 38(3):484–489. <https://dx.doi.org/10.1111/j.1524-4725.2011.02239.x>
- 208.** Cho EH, Shammass RL, Carney MJ et al. Muscle versus Fasciocutaneous Free Flaps in Lower Extremity Traumatic Reconstruction. *Plast Reconstr Surg* 2018; 141(1):191–199. <https://dx.doi.org/10.1097/PRS.0000000000003927>
- 209.** Cheng L, Yang X, Chen T, Li Z. Peroneal artery perforator flap for the treatment of chronic lower extremity wounds. *J Orthop Surg Res* 2017; 12(1):170. <https://dx.doi.org/10.1186/s13018-017-0675-z>
- 210.** Cox NH, Dyson P. Wound healing on the lower leg after radiotherapy or cryotherapy of Bowen's disease and other malignant skin lesions. *Br J Dermatol* 1995; 133(1):60–65. <https://dx.doi.org/10.1111/j.1365-2133.1995.tb02493.x>
- 211.** Karia PS, Jambusaria-Pahlajani A, Harrington DP et al. Evaluation of American Joint Committee on Cancer, International Union Against Cancer, and Brigham and Women's Hospital Tumor Staging for Cutaneous Squamous Cell Carcinoma. *J Clin Oncol* 2014; 32(4):327–334. <https://dx.doi.org/10.1200/JCO.2012.48.5326>

212. Schmults CD, Karia PS, Carter JB et al. Factors predictive of recurrence and death from cutaneous squamous cell carcinoma: a 10-year, single-institution cohort study. *JAMA Dermatol* 2013; 149(5):541–547. <https://dx.doi.org/10.1001/jamadermatol.2013.2139>
213. Rodríguez Pichardo A, García Bravo B. Dermatitis artefacta: a review. *Actas Dermo-Sifiligráficas (English Edition)* 2013; 104(10):854–866. <https://dx.doi.org/10.1016/j.adengl.2012.10.018>
214. Conde Montero E, Sánchez-Albisua B, Guisado S et al. Factitious Ulcer Misdiagnosed as Pyoderma Gangrenosum. *Wounds* 2016; 28(2):63–67
215. Koblenzer CS. Dermatitis Artefacta. *Am J Clin Dermatol* 2000; 1(1):47–55. <https://dx.doi.org/10.2165/00128071-200001010-00005>
216. Chatterjee SS, Mitra S. Dermatitis Artefacta Mimicking Borderline Personality Disorder: Sometimes, Skin Could Be Misleading. *Clin Psychopharmacol Neurosci* 2016; 14(3):311–313. <https://dx.doi.org/10.9758/cpn.2016.14.3.311>
217. Gawn RA, Kauffmann EA. Munchausen Syndrome. *BMJ* 1955; 2(4947):1068. <https://dx.doi.org/10.1136/bmj.2.4947.1068>
218. Edlich RF, Tafel JA, Smith JF, Morgan RF. Factitious skin wounds. *Compr Ther* 1987; 13(8):57–61
219. Plassmann R. The biography of the factitious-disorder patient. *Psychother Psychosom* 1994; 62(1-2):123–128. <https://dx.doi.org/10.1159/000288912>
220. Farber SK. Self-Medication, Traumatic Reenactment, and Somatic Expression in Bulimic and Self-Mutilating Behavior. *Clin Soc Work J* 1997; 25(1):87–106. <https://dx.doi.org/10.1023/A:1025785911606>
221. Gattu S, Rashid RM, Khachemoune A. Self-induced skin lesions: a review of dermatitis artefacta. *Cutis* 2009; 84(5):247–251
222. Krener P. Factitious disorders and the psychosomatic continuum in children. *Curr Opin Pediatr* 1994; 6(4):418–422. <https://dx.doi.org/10.1097/00008480-199408000-00011>
223. Gutierrez D, Schowalter MK, Piliang MP, Fernandez AP. Epidermal multinucleated keratinocytes: a histopathologic clue to dermatitis artefacta. *J Cutan Pathol* 2016; 43(10):880–883. <https://dx.doi.org/10.1111/cup.12744>
224. Winters C, Machan M, Liu D, Fraga GR. Multinucleated giant cells in factitial dermatitis. *J Cutan Pathol* 2013;40(2):205–208. <https://dx.doi.org/10.1111/cup.12080> Medline
225. Sweeney SA, Sulit DJ, Adams EG et al. Grape Cells (Multinucleated Keratinocytes) in Noninfectious Dermatoses. *Am J Dermatopathol* 2015; 37(12):e143–e146. <https://dx.doi.org/10.1097/DAD.0000000000000330>
226. Azurdia RM, Guerin DM, Sharpe GR. Recurrent bullous dermatitis artefacta mimicking immunobullous disease. *Br J Dermatol* 2000; 143(1):229–230. <https://dx.doi.org/10.1046/j.1365-2133.2000.03642.x>
227. Mohandas P, Bewley A, Taylor R. Dermatitis artefacta and artefactual skin disease: the need for a psychodermatology multidisciplinary team to treat a difficult condition. *Br J Dermatol* 2013; 169(3):600–606. <https://dx.doi.org/10.1111/bjd.12416>
228. Nielsen K, Jepsen M, Simmelsgaard L et al. Self-inflicted skin diseases. A retrospective analysis of 57 patients with dermatitis artefacta seen in a dermatology department. *Acta Derm Venereol* 2005; 85(6):512–515
229. Orbuch DE, Kim RH, Cohen DE. Ecthyma: a potential mimicker of zoonotic infections in a returning traveler. *Int J Infect Dis* 2014; 29:178–180. <https://dx.doi.org/10.1016/j.ijid.2014.08.014>
230. Greene SL, Daniel Su WVP, Muller SA. Ecthyma gangrenosum: Report of clinical, histopathologic, and bacteriologic aspects of eight cases. *J Am Acad Dermatol* 1984; 11(5):781–787. [https://dx.doi.org/10.1016/S0190-9622\(84\)80453-3](https://dx.doi.org/10.1016/S0190-9622(84)80453-3)
231. Reich HL, Williams Fadeyi D, Naik NS et al. Nonpseudomonal ecthyma gangrenosum. *J Am Acad Dermatol* 2004; 50(5 Suppl):114–117. <https://dx.doi.org/10.1016/j.jaad.2003.09.019>
232. Huminer D, Siegman-Igra Y, Morduchowicz G, Pitlik SD. Ecthyma gangrenosum without bacteremia. Report of six cases and review of the literature. *Arch Intern Med* 1987; 147(2):299–301. <https://dx.doi.org/10.1001/archinte.1987.00370020117047>
233. Vaiman M, Lasarovitch T, Heller L, Lotan G. Ecthyma gangrenosum versus ecthyma-like lesions: should we separate these conditions? *Acta Dermatovenerol Alp Pannonica Adriat* 2015; 24(4):69–72
234. Karimi K, Odhav A, Kollipara R et al. Acute Cutaneous Necrosis: A Guide to Early Diagnosis and Treatment. *J Cutan Med Surg* 2017; 21(5):425–437. <https://dx.doi.org/10.1177/1203475417708164>
235. Soria A, Francès C, Guihot A et al. [Etiology of ecthyma gangrenosum (four cases)]. *Ann Dermatol Venereol* 2010 Jun; 137(6-7):472–476. <https://dx.doi.org/10.1016/j.annder.2010.04.013>
236. Son YM, Na SY, Lee HY et al. Ecthyma Gangrenosum: A Rare Cutaneous Manifestation Caused by Stenotrophomonas maltophilia in a Leukemic Patient. *Ann Dermatol* 2009; 21(4):389–392. <https://dx.doi.org/10.5021/ad.2009.21.4.389>
237. Boisseau AM, Sarlangue J, Perel Y et al. Perineal ecthyma gangrenosum in infancy and early childhood: Septicemic and nonsepticemic forms. *J Am Acad Dermatol* 1992; 27(3):415–418. [https://dx.doi.org/10.1016/0190-9622\(92\)70210-7](https://dx.doi.org/10.1016/0190-9622(92)70210-7)
238. Zomorrodi A, Wald ER. Ecthyma gangrenosum: considerations in a previously healthy child. *Pediatr Infect Dis J* 2002; 21(12):1161–1164. <https://dx.doi.org/10.1097/00006454-200212000-00016>
239. O'Sullivan GM, Worsnop F, Natkunarajah J. Ecthyma gangrenosum, an important cutaneous infection to recognize in the immunosuppressed patient. *Clin Exp Dermatol* 2018; 43(1):67–69. <https://dx.doi.org/10.1111/ced.13253>
240. Blumenthal NC, Sood UR, Aronson PJ, Hashimoto K. Facial ulcerations in an immunocompromised patient. *Ecthyma gangrenosum*. *Arch Dermatol* 1990; 126(4):529. <https://dx.doi.org/10.1001/archderm.126.4.529>
241. Weston G, Payette M. Update on lichen planus and its clinical variants. *Int J Womens Dermatol* 2015 Aug; 1(3):140–149. <https://dx.doi.org/10.1016/j.ijwd.2015.04.001> Medline
242. Sälävästru C, Tiplica GS. Therapeutic hotline: ulcerative lichen planus - treatment challenges. *Dermatol Ther* 2010; 23(2):203–205. <https://dx.doi.org/10.1111/j.1529-8019.2010.01316.x>
243. Desroche T, Moawad S, Cuny JF et al. Bilateral squamous cell carcinoma arising from cutaneous ulcerative lichen planus of the extremities: two case reports. *Eur J Dermatol* 2018; 28(3):391–392
244. Feily A, Mehraban S. Treatment modalities of necrobiosis lipoidica: a concise systematic review. *Dermatol Rep* 2015; 7(2):5749. <https://dx.doi.org/10.4081/dr.2015.5749>
245. O'Toole EA, Kennedy U, Nolan JJ et al. Necrobiosis lipoidica: only a minority of patients have diabetes mellitus. *Br J Dermatol* 1999; 140(2):283–286. <https://dx.doi.org/10.1046/j.1365-2133.1999.02663.x>
246. Nelzén O, Bergqvist D, Lindhagen A. Venous and non-venous leg ulcers: Clinical history and appearance in a population study. *Br J Surg* 1994; 81(2):182–187. <https://dx.doi.org/10.1002/bjs.1800810206>
247. Nakajima T, Tanemura A, Inui S, Katayama I. Venous insufficiency in patients with necrobiosis lipoidica. *J Dermatol* 2009; 36(3):166–169. <https://dx.doi.org/10.1111/j.1346-8138.2009.00612.x>
248. Santos-Juanes J, Galache C, Curto JR et al. Squamous cell carcinoma arising in long-standing necrobiosis lipoidica. *J Eur Acad Dermatol Venereol* 2004; 18(2):199–200. <https://dx.doi.org/10.1111/j.1468-3083.2004.00444.x>
249. Yoo SS, Mimouni D, Nikolskaia OV et al. Clinicopathologic features of ulcerative-atrophic sarcoidosis. *Int J Dermatol* 2004; 43(2):108–112. <https://dx.doi.org/10.1111/j.1365-4632.2004.01896.x>
250. Albertini JG, Tyler W, Miller OF 3rd. Ulcerative Sarcoidosis. Case report and review of the literature. *Arch Dermatol* 1997; 133(2):215–219. <https://dx.doi.org/10.1001/archderm.1997.03890380087013>
251. Phillips MA, Lynch J, Azmi FH. Ulcerative cutaneous sarcoidosis responding to adalimumab. *J Am Acad Dermatol* 2005; 53(5):917. <https://dx.doi.org/10.1016/j.jaad.2005.02.023>

- 252.** Thurtle OA, Cawley MI. The frequency of leg ulceration in rheumatoid arthritis: a survey. *J Rheumatol* 1983; 10(3):507–509
- 253.** Mekkes JR, Loots MA, Van Der Wal AC, Bos JD. Causes, investigation and treatment of leg ulceration. *Br J Dermatol* 2003; 148(3):388–401. <https://dx.doi.org/10.1046/j.1365-2133.2003.05222.x>
- 254.** Lam G, Ross FL, Chiu ES. Nonhealing Ulcers in Patients with Tophaceous Gout. *Adv Skin Wound Care* 2017; 30(5):230–237. <https://dx.doi.org/10.1097/01.ASW.0000515456.65405.56>
- 255.** Meunier P, Dequid L, Barnette T et al. Increased risk of mortality in systemic sclerosis-associated digital ulcers: a systematic review and meta-analysis. *J Eur Acad Dermatol Venereol* 2018; 33(2):405–409. <https://dx.doi.org/10.1111/jdv.15114>
- 256.** Montefusco E, Alimena G, Gastaldi R et al. Unusual dermatologic toxicity of long-term therapy with hydroxyurea in chronic myelogenous leukemia. *Tumor Journal* 1986; 72(3):317–321. <https://dx.doi.org/10.1177/030089168607200314>
- 257.** Quattrone F, Dini V, Barbanera S et al. Cutaneous ulcers associated with hydroxyurea therapy. *J Tissue Viability* 2013; 22(4):112–121. <https://dx.doi.org/10.1016/j.jtv.2013.08.002>
- 258.** Flores F, Eaglstein WA, Kirsner RS. Hydroxyurea-induced leg ulcers treated with Apligraf. *Ann Intern Med* 2000; 132(5):417–418. <https://dx.doi.org/10.7326/0003-4819-132-5-200003070-00017>
- 259.** Chen TJ, Chung WH, Chen CB et al. Methotrexate-induced epidermal necrosis: A case series of 24 patients. *J Am Acad Dermatol* 2017; 77(2):247–255.e2. <https://dx.doi.org/10.1016/j.jaad.2017.02.021>
- 260.** Mönch S, Zimmo B, El Helou T, Colmegna I. Methotrexate-Induced Cutaneous Erosions. *Arthritis Rheumatol* 2016; 68(1):254. <https://dx.doi.org/10.1002/art.39409>
- 261.** Jörg I, Fenyvesi T, Harenberg J. Anticoagulant-related skin reactions. *Expert Opin Drug Saf* 2002; 1(3):287–294. <https://dx.doi.org/10.1517/14740338.1.3.287>
- 262.** Watson A, Ozairi OA, Fraser A et al. Nicorandil associated anal ulceration. *Lancet* 2002; 360(9332):546–547. [https://dx.doi.org/10.1016/S0140-6736\(02\)09710-6](https://dx.doi.org/10.1016/S0140-6736(02)09710-6)
- 263.** Reichert S, Antunes A, Trechot P. Major aphthous stomatitis induced by nicorandil. *Eur J Dermatol* 1997; 7:1321–133.
- 264.** Burza S, Croft SL, Boelaert M. Leishmaniasis. *Lancet* 2018; 392(10151):951–970. [https://dx.doi.org/10.1016/S0140-6736\(18\)31204-2](https://dx.doi.org/10.1016/S0140-6736(18)31204-2)
- 265.** Steinberg JP, Galindo RL, Kraus ES, Ghanem KG. Disseminated acanthamebiasis in a renal transplant recipient with osteomyelitis and cutaneous lesions: case report and literature review. *Clin Infect Dis* 2002; 35(5):e43–e49. <https://dx.doi.org/10.1086/341973>
- 266.** Verma GK, Sharma NL, Shanker V et al. Amoebiasis cutis: Clinical suspicion is the key to early diagnosis. *Australas J Dermatol* 2010; 51(1):52–55. <https://dx.doi.org/10.1111/j.1440-0960.2009.00594.x>
- 267.** Franco-Paredes C, Marcos LA, Henao-Martínez AF et al. Cutaneous Mycobacterial Infections. *Clin Microbiol Rev* 2018; 32(1):e00069-18. <https://dx.doi.org/10.1128/CMR.00069-18>
- 268.** Kentley J, Marshall C, Gkini M et al. Atypical Trigeminal Trophic Syndrome: An Unusual Cause of Facial Ulceration. *Acta Derm Venereol* 2017; 97(8):971–972. <https://dx.doi.org/10.2340/00015555-2675>
- 269.** Senet P, Blas-Chatelain C, Levy P et al. Factors predictive of leg-ulcer healing in sickle cell disease: a multicentre, prospective cohort study. *Br J Dermatol* 2017; 177(1):206–211. <https://dx.doi.org/10.1111/bjd.15241>
- 270.** Morton LM, Phillips TJ. Wound healing and treating wounds. *J Am Acad Dermatol* 2016; 74(4):589–605. <https://dx.doi.org/10.1016/j.jaad.2015.08.068>
- 271.** Alavi A, Niakosari F, Sibbald RG. When and how to perform a biopsy on a chronic wound. *Adv Skin Wound Care* 2010; 23(3):132–140. <https://dx.doi.org/10.1097/01.ASW.0000363515.09394.66>
- 272.** Weedon D, Patterson JW. *Weedon's skin pathology*, 4th edn. Elsevier; 2015
- 273.** Misciali C, Dika E, Baraldi C et al. Vascular leg ulcers: histopathologic study of 293 patients. *Am J Dermatopathol* 2014; 36(12):977–983. <https://dx.doi.org/10.1097/DAD.0000000000000141>
- 274.** Elston DM, Stratman EJ, Miller SJ. Skin biopsy. *J Am Acad Dermatol* 2016; 74(1):1–16. <https://dx.doi.org/10.1016/j.jaad.2015.06.033>
- 275.** Carlson JA. The histological assessment of cutaneous vasculitis. *Histopathology* 2010; 56(1):3–23. <https://dx.doi.org/10.1111/j.1365-2559.2009.03443.x>
- 276.** Calonje JE, Brenn T, Lazar A, McKee P. *McKee's pathology of the skin*, 4th edn. Saunders; 2012
- 277.** Kazandjieva J, Antonov D, Kamarashev J, Tsankov N. Acrally distributed dermatoses: Vascular dermatoses (purpura and vasculitis). *Clin Dermatol* 2017; 35(1):68–80. <https://dx.doi.org/10.1016/j.clindermatol.2016.09.013>
- 278.** Hafner J, Nobbe S, Partsch H et al. Martorell hypertensive ischaemic leg ulcer: A model of ischemic subcutaneous arteriosclerosis. *Arch Dermatol* 2010; 146(9):961–968
- 279.** Chen TY, Lehman JS, Gibson LE et al. Histopathology of Calciphylaxis. *Am J Dermatopathol* 2017; 39(11):795–802. <https://dx.doi.org/10.1097/DAD.0000000000000824>
- 280.** Ahmed I, Goldstein B. Diabetes mellitus. *Clin Dermatol* 2006 Jul; 24(4):237–246. <https://dx.doi.org/10.1016/j.clindermatol.2006.04.009> Medline
- 281.** Markey AC, Tidman MJ, Rowe PH et al. Aggressive ulcerative necrobiosis lipoidica associated with venous insufficiency, giant-cell phlebitis and arteritis. *Clin Exp Dermatol* 1988; 13(3):183–186. <https://dx.doi.org/10.1111/j.1365-2230.1988.tb01966.x>
- 282.** Wick MR. Granulomatous & histiocytic dermatitides. *Semin Diagn Pathol* 2017; 34(3):301–311. <https://dx.doi.org/10.1053/j.semdp.2016.12.003>
- 283.** Baldursson BT, Hedblad MA, Beitner H, Lindelöf B. Squamous cell carcinoma complicating chronic venous leg ulceration: a study of the histopathology, course and survival in 25 patients. *Br J Dermatol* 1999; 140(6):1148–1152. <https://dx.doi.org/10.1046/j.1365-2133.1999.02879.x>
- 284.** Wilcox RA. Cutaneous B-cell lymphomas: 2016 update on diagnosis, risk-stratification, and management. *Am J Hematol* 2016; 91(10):1052–1055. <https://dx.doi.org/10.1002/ajh.24462>
- 285.** Mansur AT, Demirci GT, Ozel O et al. Acral melanoma with satellitosis, disguised as a longstanding diabetic ulcer: a great mimicry. *Int Wound J* 2016; 13(5):1006–1008. <https://dx.doi.org/10.1111/iwj.12481>
- 286.** Sirieix ME, Debure C, Baudot N et al. Leg ulcers and hydroxyurea: forty-one cases. *Arch Dermatol* 1999; 135(7):818–820. <https://dx.doi.org/10.1001/archderm.135.7.818>
- 287.** Chan YC, Valenti D, Mansfield AO, Stansby G. Warfarin induced skin necrosis. *Br J Surg* 2000; 87(3):266–272. <https://dx.doi.org/10.1046/j.1365-2168.2000.01352.x>
- 288.** Moore Z, Butcher G, Corbett LQ et al. AAWC, AWMA, EWMA position paper: managing wounds as a team. *J Wound Care* 2014; 23(5 Suppl):S1–S38
- 289.** Goeser MR, Laniosz V, Wetter DA. A practical approach to the diagnosis, evaluation, and management of cutaneous small-vessel vasculitis. *Am J Clin Dermatol* 2014; 15(4):299–306. <https://dx.doi.org/10.1007/s40257-014-0076-6>
- 290.** Sharma AM, Singh S, Lewis JE. Diagnostic approach in patients with suspected vasculitis. *Tech Vasc Interv Radiol* 2014; 17(4):226–233. <https://dx.doi.org/10.1053/j.tvir.2014.11.002>
- 291.** Pichler M, Larcher L, Holzer M et al. Surgical treatment of pyoderma gangrenosum with negative pressure wound therapy and split thickness skin grafting under adequate immunosuppression is a valuable treatment option: Case series of 15 patients. *J Am Acad Dermatol* 2016; 74(4):760–765. <https://dx.doi.org/10.1016/j.jaad.2015.09.009>

- 292.** Bosanquet DC, Rangaraj A, Richards AJ et al. Topical steroids for chronic wounds displaying abnormal inflammation. *Ann R Coll Surg Engl* 2013; 95(4):291–296. <https://dx.doi.org/10.1308/003588413X13629960045634>
- 293.** Carre D, Domp Martin A, Gislard A et al. [Benefit of topical steroids in necrotic angiodermitis]. [In French] *Ann Dermatol Venereol* 2003; 130(5):547–548
- 294.** Piaggese A, Läubli S, Bassetto F et al. EWMA document: advanced therapies in wound management: cell and tissue based therapies, physical and bio-physical therapies smart and IT based technologies. *J Wound Care* 2018; 27(6); Suppl 6
- 295.** Richmond NA, Lamel SA, Braun LR et al. Epidermal grafting using a novel suction blister-harvesting system for the treatment of pyoderma gangrenosum. *JAMA Dermatol* 2014; 150(9):999–1000. <https://dx.doi.org/10.1001/jamadermatol.2014.1431>
- 296.** Nordström A, Hansson C. Punch-grafting to enhance healing and to reduce pain in complicated leg and foot ulcers. *Acta Derm Venereol* 2008; 88(4):389–391
- 297.** Fourgeaud C, Mouloise G, Michon-Pasturel U et al. Interest of punch skin grafting for the treatment of painful ulcers. *J Mal Vasc* 2016; 41(5):329–334. <https://dx.doi.org/10.1016/j.jmv.2016.08.002>
- 298.** Partsch H, Mortimer P. Compression for leg wounds. *Br J Dermatol* 2015; 173(2):359–369. <https://dx.doi.org/10.1111/bjd.13851>
- 299.** Simmons J. Getting ready for wound certification. *J Wound Ostomy Continence Nurs* 2018; 45(5):474–476. <https://dx.doi.org/10.1097/WON.0000000000000464>
- 300.** Pieper, B. Atypical Lower extremity wounds. Doughty DBMc Nichol LL. *Core Curric. Wound Manag. Philadelphia* 515–529 (2016).
- 301.** Agarwal A, Cardones AR. Wounds caused by dermatologic conditions. Doughty DB Mc Nichol LL. *Core Curriculum: Wound Management, Philadelphia*, 2016: 573-585
- 302.** Sussman G. Ulcer dressings and management. *Aust Fam Physician* 2014; 43(9):588–592
- 303.** Huang CY, Choong MY, Li TS. Cleansing of wounds by tap water? An evidence-based systemic analysis. *Int Wound J* 2015; 12(4):493–494. <https://dx.doi.org/10.1111/iwj.12113>
- 304.** Hodgkinson B, Nay R. Effectiveness of topical skin care provided in aged care facilities. *Int J Evid Based Healthc* 2005; 3(4):65–101
- 305.** Venous Leg Ulcers. (2014).
- 306.** Nix D, Haugen V. Prevention and management of incontinence-associated dermatitis. *Drugs Aging* 2010; 27(6):491–496. <https://dx.doi.org/10.2165/11315950-000000000-00000>
- 307.** Cooper, R. A review of the evidence of the use of topical antimicrobial agents in wound care. *World Wound* 11, (2005).
- 308.** White R. An interview with Richard White. *Br J Community Nurs* 2014; 19(Sup6 Suppl):S54–S55. <https://dx.doi.org/10.12968/bjcn.2014.19.Sup6.S54>
- 309.** White R, Lindsey E, Fletcher J et al. Leg ulcer care: Should we be washing the legs and taking time for effective skin care? *Wounds UK* 2016; 12:12–16.
- 310.** Harding KG, Morris HL, Patel GK. Science, medicine, and the future: Healing chronic wounds. *BMJ* 2002; 324(7330):160–163. <https://dx.doi.org/10.1136/bmj.324.7330.160>
- 311.** Schultz GS, Sibbald RG, Falanga V et al. Wound bed preparation: a systematic approach to wound management. *Wound Repair Regen* 2003; 11(s1 Suppl 1):S1–S28. <https://dx.doi.org/10.1046/j.1524-475X.11.s2.1.x>
- 312.** Taheri A, Mansoori P, Al-Dabagh A, Feldman SR. Are corticosteroids effective for prevention of scar formation after second-degree skin burn? *J Dermatolog Treat* 2014; 25(4):360–362. <https://dx.doi.org/10.3109/09546634.2013.806768>
- 313.** Hofman D, Moore K, Cooper R et al. Use of topical corticosteroids on chronic leg ulcers. *J Wound Care* 2007; 16(5):227–230. <https://dx.doi.org/10.12968/jowc.2007.16.5.27047>
- 314.** Wicke C, Halliday B, Allen D et al. Effects of steroids and retinoids on wound healing. *Arch Surg* 2000; 135(11):1265–1270. <https://dx.doi.org/10.1001/archsurg.135.11.1265>
- 315.** Leaper DJ, Schultz G, Carville K et al. Extending the TIME concept: what have we learned in the past 10 years? *Int Wound J* 2012; 9 Suppl 2:1–19. <https://dx.doi.org/10.1111/iwj.1742-481X.2012.01097.x>
- 316.** Cooper R, Kirketerp-Møller K. Non-antibiotic antimicrobial interventions and antimicrobial stewardship in wound care. *J Wound Care* 2018; 27(6):355–377. <https://dx.doi.org/10.12968/jowc.2018.27.6.355>
- 317.** Gottrup F, Apelqvist J, Bjarnsholt T et al. EWMA document: Antimicrobials and non-healing wounds. Evidence, controversies and suggestions. *J Wound Care* 2013; 22(Sup5 Suppl):S1–S89. <https://dx.doi.org/10.12968/jowc.2013.22.Sup5.S1> Medline
- 318.** Romaneli M, Weir D. Exudate management made easy. *Wounds UK* 1, (2010).
- 319.** Mudge E, Orsted H. Wound infection and pain management. *Made Easy. Wounds Int* 2010; 1:1–6.
- 320.** Agathangelou C, Fletcher J, HariKrishna, R. N et al. PolyMem dressings Made Easy. *Wounds UK* 1–4 (2015).
- 321.** Apelqvist J, Willy C, Fagerdahl AM et al. EWMA Document: Negative Pressure Wound Therapy. *J Wound Care* 2017; 26 Sup3:S1–S154. <https://dx.doi.org/10.12968/jowc.2017.26.Sup3.S1>
- 322.** Deufert D, Graml R. Disease-specific, health-related quality of life (HRQoL) of people with chronic wounds—A descriptive cross-sectional study using the Wound-QoL. *Wound Medicine* 2017; 16:29–33. <https://dx.doi.org/10.1016/j.wndm.2017.01.006>
- 323.** Moch SD. Personal knowing: evolving research and practice. *Sch Inq Nurs Pract* 1990;4(2):155–165
- 324.** International consensus. Making the case for cost-effective wound management. *Wounds Int*. (2013).
- 325.** International Best Practice Statement: Optimising patient involvement in wound management. *Wounds International*, 2016
- 326.** Weenig RH, Davis MD, Dahl PR, Su WP. Skin ulcers misdiagnosed as pyoderma gangrenosum. *N Engl J Med* 2002; 347(18):1412–1418. <https://dx.doi.org/10.1056/NEJMoa013383>
- 327.** Van Hecke A, Beeckman D, Grypdonck M et al. Knowledge deficits and information-seeking behavior in leg ulcer patients: an exploratory qualitative study. *J Wound Ostomy Continence Nurs* 2013;40(4):381–387. <https://dx.doi.org/10.1097/WON.0b013e31829a2f4d>
- 328.** Hammar T, Nilsson AL, Hovstadius B. Patients' views on electronic patient information leaflets. *Pharmacy Practice* 2016; 14(2):702. <https://dx.doi.org/10.18549/PharmPract.2016.02.702>
- 329.** Bentley J. Assess, negotiate, treat: community prescribing for chronic wounds. *Br J Community Nurs* 2001; 6(6):302–312. <https://dx.doi.org/10.12968/bjcn.2001.6.6.7076>
- 330.** Bethell E, Cadogan J, Charles DH et al. Issues in wound care: empowering patients - developing a framework for practitioners. *J Wound Care* 2006; 15(2):62–63. <https://dx.doi.org/10.12968/jowc.2006.15.2.26889>
- 331.** Elzen H, Slaets JP, Srijders TA, Steverink N. Evaluation of the chronic disease self-management program (CDSMP) among chronically ill older people in the Netherlands. *Soc Sci Med* 2007; 64(9):1832–1841. <https://dx.doi.org/10.1016/j.socscimed.2007.02.008>
- 332.** Kulzer B, Hermanns N, Reinecker H, Haak T. Effects of self-management training in Type 2 diabetes: a randomized, prospective trial. *Diabet Med* 2007; 24(4):415–423. <https://dx.doi.org/10.1111/j.1464-5491.2007.02089.x>
- 333.** Green J, Jester R, McKinley R, Pooler A. Nurse-patient consultations in primary care: do patients disclose their concerns? *J Wound Care* 2013; 22(10):534–539. <https://dx.doi.org/10.12968/jowc.2013.22.10.534>
- 334.** De Souza Leal T, De Oliveira B, Santos Bomfim E et al. Perception of people with chronic wound. *J Nurs Recife* 2017; 11(3):1156–1162

- 335.** Upton D, Upton P, Alexander R. Contribution of the Leg Club model of care to the well-being of people living with chronic wounds. *J Wound Care* 2015; 24(9):397–405. <https://dx.doi.org/10.12968/jowc.2015.24.9.397>
- 336.** Augustin M, Herberger K, Rustenbach SJ, Schäfer I, Zschocke I, Blome C. Quality of life evaluation in wounds: validation of the Freiburg Life Quality Assessment-wound module, a disease-specific instrument. *Int Wound J* 2010; 7(6):493–501. <https://dx.doi.org/10.1111/j.1742-481X.2010.00732.x>
- 337.** McMath E, Harvey C. Complex wounds: a partnership approach to patient documentation. *Br J Nurs* 2004; 13 Sup2:S12–S16. <https://dx.doi.org/10.12968/bjon.2004.13.Sup2.13234>
- 338.** Wilson J, Arshad F, Nnamoko N et al. Patient-reported outcome measures: an on-line system empowering patient choice. *J Am Med Inform Assoc* 2014; 21(4):725–729. <https://dx.doi.org/10.1136/amiajnl-2012-001183>
- 339.** Mason JM, Thomas KS, Ormerod AD et al. Ciclosporin compared with prednisolone therapy for patients with pyoderma gangrenosum: cost-effectiveness analysis of the STOP GAP trial. *Br J Dermatol* 2017; 177(6):1527–1536. <https://dx.doi.org/10.1111/bjd.15561>
- 340.** Gottrup F, Apelqvist J, Price P et al. Outcomes in controlled and comparative studies on non-healing wounds: recommendations to improve the quality of evidence in wound management. *J Wound Care* 2010; 19(6):237–268. <https://dx.doi.org/10.12968/jowc.2010.19.6.48471>
- 341.** Guest JF, Ayoub N, McLlwrath T et al. Health economic burden that wounds impose on the National Health Service in the UK. *BMJ Open* 2015; 5(12):e009283. <https://dx.doi.org/10.1136/bmjopen-2015-009283>
- 342.** Graves N, Zheng H. Modelling the direct health care costs of chronic wounds in Australia. *Wound Pract Res* 2014; 22:20.
- 343.** Posnett J, Gottrup F, Lundgren H, Saal G. The resource impact of wounds on health-care providers in Europe. *J Wound Care* 2009; 18(4):154–161. <https://dx.doi.org/10.12968/jowc.2009.18.4.1607>
- 344.** Phillips CJ, Humphreys I, Fletcher J et al. Estimating the costs associated with the management of patients with chronic wounds using linked routine data. *Int Wound J* 2016; 13(6):1193–1197. <https://dx.doi.org/10.1111/iwj.12443>
- 345.** Khalsa A, Liu G, Kirby JS. Increased utilization of emergency department and inpatient care by patients with hidradenitis suppurativa. *J Am Acad Dermatol* 2015; 73(4):609–614. <https://dx.doi.org/10.1016/j.jaad.2015.06.053>
- 346.** Desai N, Shah P. High burden of hospital resource utilization in patients with hidradenitis suppurativa in England: a retrospective cohort study using hospital episode statistics. *Br J Dermatol* 2017; 176(4):1048–1055. <https://dx.doi.org/10.1111/bjd.14976>
- 347.** Matusiak Ł, Bieniek A, Szepietowski JC. Hidradenitis suppurativa markedly decreases quality of life and professional activity. *J Am Acad Dermatol*. 62, 706–708, 708.e1 (2010).
- 348.** Cancer Council. Skin Cancer. <https://www.cancer.org.au/about-cancer/types-of-cancer/skin-cancer.html>. (accessed 15 May 2019)
- 349.** Cancer Council. Skincancer incidence and mortality. <https://tinyurl.com/y6efalcr>. (accessed 15 May 2019)
- 350.** Graves N, Finlayson K, Gibb M et al. Modelling the economic benefits of gold standard care for chronic wounds in a community setting. *Wound Pract Res* 2014; 22:163.
- 351.** Hjort A, Gottrup F. Cost of wound treatment to increase significantly in Denmark over the next decade. *J Wound Care* 2010; 19(5):173–184. <https://dx.doi.org/10.12968/jowc.2010.19.5.48046>
- 352.** Norman G, Atkinson RA, Smith TA et al. Intracavity lavage and wound irrigation for prevention of surgical site infection. *Cochrane Database Syst Rev* 2017; 10:CD012234. <https://dx.doi.org/10.1002/14651858.CD012234.pub2>
- 353.** Rybak Z, Franks PJ, Krasowski G et al. Strategy for the treatment of chronic leg wounds: a new model in Poland. *Int Angiol* 2012; 31(6):550–556
- 354.** Edwards H, Finlayson K, Courtney M et al. Health service pathways for patients with chronic leg ulcers: identifying effective pathways for facilitation of evidence based wound care. *BMC Health Serv Res* 2013; 13(1):86. <https://dx.doi.org/10.1186/1472-6963-13-86>
- 355.** Snyder RJ, Lantis J, Kirsner RS et al. Macrophages: A review of their role in wound healing and their therapeutic use. *Wound Repair Regen* 2016; 24(4):613–629. <https://dx.doi.org/10.1111/wrr.12444>

18. Glossary

Definitions

Biologic treatment: a type of treatment that uses substances made from living organisms to treat disease. Types of biological therapy include immunotherapy (such as vaccines, cytokines, and some antibodies), gene therapy, and some targeted therapies.

Cribriform: scars perforated like a sieve

Immunomodulatory therapy: treatment that modulates the activity of the body's immune system.

Immunosuppressive therapy: treatment that lowers the activity of the body's immune system

Multidisciplinary team: a multidisciplinary team is a group of health care workers who are members of different disciplines each providing specific services to the patient. The team members independently treat various issues a patient may have, focusing on the issues in which they specialise¹.

Interdisciplinary team: An interdisciplinary clinical team is a consistent grouping of people from relevant clinical disciplines, ideally inclusive of the patient, whose interactions are guided by specific team functions and processes to achieve team-defined favourable patient outcomes.²

Pathergy: A skin condition in which a minor trauma leads to the development of specific skin lesions.

Purpura: Red to dark purple spots in the skin that do not disappear on compression. Associated with vessel damage in the dermis.

Systemic treatment: Treatment using substances that travel through the bloodstream, reaching and affecting cells all over the body.

Abbreviations

AAV: ANCA-associated vasculitides

ADA2: Adenosine deaminase²

ABPI: Ankle-brachial pressure index

ANA: Antinuclear antibodies

ANCA: Antineutrophilic cytoplasmic antibodies

BAD: British Association of Dermatology

BCC: Basal cell carcinomas

BMP: Bone morphogenetic proteins

BSAC: British Society for Antimicrobial Chemotherapy

CHCC: Chapel Hill Consensus Conference Nomenclature of Vasculitides

CPAN: Cutaneous polyarteritis nodosa

CTD: Connective tissue disorder

CUA: Calcific uremic arteriolopathy	IgAV: IgA vasculitis
DIF: Direct immunofluorescence	IL-1/12/17: Interleukin
EB: Epidermolysis bullosa	IRD: Inflammatory rheumatological diseases
EG: Ecthyma gangrenosum	LCV: Leukocytoclastic vasculitis
EGPA: Eosinophilic granulomatosis with polyangiitis	LE: Lupus erythematosus
ELISA: Enzyme-linked immunosorbent assay	LP: Lichen planus
ESRD: End-stage renal disease	LU: Leg ulcer
EWMA: European Wound Management Association	LV: Livedoid vasculopathy
GPA: Granulomatosis with polyangiitis	MGP: Matrix Gla protein
HE: Haematoxylin and eosin stain	MMP: Matrix metalloproteinase
HSP: Henoch-Schönlein purpura	MPA: Microscopic polyangiitis
HHV8: Human herpes virus 8	MPO-ANCA: Myeloperoxidase ANCA
HRQoL: Health Related Quality of Life	MRI: Magnetic resonance imaging
HS: Hidradenitis suppurativa	MVV: Medium vessel vasculitis
HT: Hypertension	NETs: Neutrophil extracellular traps
HYTILU: Hypertensive ischemic leg ulcer	NHS: National health service
IBD: Inflammatory bowel diseases	NL: Necrobiosis lipoidica
IgA/G/M: Immunoglobulin A/G/M	NMSC: Non-melanoma skin cancer

NPWT: Negative pressure wound therapy	PTA: Percutaneous transluminal angioplasty
NSAID: Non-Steroidal Anti-Inflammatory Drug	PTP: Protein tyrosine phosphatases
PAD: Peripheral arterial disease	PURPLE: Painful Purpuric Ulcers with Reticular Pattern of the Lower Extremities
PAN: Polyarteritis nodosa	RA: Rheumatoid arthritis
PAPA: PG, Pyogenic arthritis, and Acne	RCT: Randomised controlled trials
PAS: Periodic acid–Schiff staining	SCC: Squamous cell carcinomas
PASH: PG, Pyogenic arthritis and Hidradenitis suppurativa	SCD: Sickle cell disease
PA-PASH: PG, Pyogenic arthritis, Hidradenitis suppurativa, and Acne	SLE: Systemic lupus erythematosus
PCR: Polymerase chain reaction	SOV: Single organ vasculitis
PEST: Proline, glutamate, serine and threonine	SSI: Surgical site infection
PF: Purpura fulminans	SSRI: Serotonin reuptake inhibitor
PMN: Polymorphonuclear leukocytes	SVV: Small vessel vasculitis
PR3-ANCA: Proteinase 3 ANCA	TNF-α: Tumour necrosis factor alpha
PROMS: Patient related outcome measurements	ULP: Ulcerative lichen planus
PSPG: Postsurgical pyoderma gangrenosum	UVA1: Ultraviolet A1